

Keratinocyte dysplasia in organ transplant recipients:
Treatment and prevention with photodynamic therapy and
non-invasively measured skin photodamage

Katrine Togsverd-Bo MD, ph.d.

The Faculty of Health and Medical Sciences at the University of Copenhagen has accepted this dissertation for public defence for the doctoral degree in medicine.

Copenhagen, June 12th 2020. Ulla Wewer, Head of Faculty.

The defence will take place Friday the 30th October 2020 at 15.30 in the Henrik Dam auditorium, Panum Institute, University of Copenhagen.

ISBN: 978-87-93510-58-6

Preface

This thesis is based on experiments performed at the Department of Dermatology, Bispebjerg Hospital, Copenhagen between 2009 and 2016.

For the becoming of this thesis, I owe my warmest thanks to Professor Merete Hædersdal, MD, PhD and DMSc who has never stopped encouraging me to pursue new scientific and personal achievements. I have never doubted your support and faith in me. Thank you. Second, I would like to thank Professor Hans Christian Wulf, MD, DMSc for great scientific discussions and for continuously providing me with ideas for experiments.

I want to thank my co-authors for participation, with engaging discussions and willingness to help make these studies and papers come to life. A special thanks goes to Peter Philipsen, MSc, PhD and Catharina Lerche cand.pharm., PhD for scientific and statistical guidance; and warm thank you to Professor Søren Schwartz Sørensen, MD, DMSc for invaluable input on transplant patients. Finally, I am grateful for everyone at D92 throughout the years for numerous pep-talks, cake and good spirits.

Last, but not least, the studies and thesis would never have been completed without the support of my family. Your never-ending encouragement, patience and emotional support have carried me through challenging times. This thesis is dedicated to you.

Contents

1	Papers	5
2	Abbreviations and Definitions	6
3	Introduction	8
3.1	Aim of the Thesis	11
4	Background	12
4.1	Ultraviolet radiation	12
4.2	Photodynamic therapy	15
4.3	Ablative fractional lasers and PDT	19
4.4	Organ transplant recipients and keratinocyte dysplasia	21
5	Methods	24
5.1	PDT treatments	24
5.2	Clinical evaluations	25
5.3	AFL treatment	25
5.4	Protoporphyrin IX fluorescence	26
5.5	Non-invasive measurements of skin photodamage	26
5.6	Personal electronic UVR dosimeters and sun exposure diaries	27
6	Results and Discussion	29
6.1	PDT efficacy	29
6.2	PDT for prevention of skin dysplasia	32
6.3	Non-invasive measurements of skin photodamage and UVR exposure	35
7	Conclusions	38
8	Perspectives	40
9	Dansk resume	42
10	Reference List	44
11	Appendix	62

1 Papers

- I. Togsverd-Bo K, Halldin C, Sandberg C, Gonzales H, Wennberg AM, Sørensen SS, Wulf HC, Hædersdal M. *Photodynamic therapy is more effective than imiquimod for actinic keratoses in organ transplant recipients: a randomized intraindividual controlled trial.* British Journal of Dermatology 2018;178: 903-909.
- II. Togsverd-Bo K, Lei U, Erlendsson AM, Taudorf EH, Philipsen PA, Wulf HC, Skov L, Hædersdal M. *Combination of ablative fractional laser and daylight-mediated photodynamic therapy for actinic keratosis in organ transplant recipients – a randomized controlled trial.* British Journal of Dermatology 2015;172: 467-474.
- III. Helsing P, Togsverd-Bo K, Veierød MB, Mørk G, Hædersdal M. *Intensified fractional CO₂ laser-assisted photodynamic therapy vs. laser alone for organ transplant recipients with multiple actinic keratosis and wart-like lesions: a randomized half-side comparative trial on dorsal hands.* British Journal of Dermatology 2013;169: 1087-1092.
- IV. Togsverd-Bo K, Omland SH, Wulf HC; Sørensen SS, Hædersdal M. *Primary prevention of skin dysplasia in renal transplant recipients with photodynamic therapy: A randomized controlled trial.* American Journal of Transplantation 2015;15: 2986-2990.
- V. Togsverd-Bo K, Lerche CM, Philipsen PA, Hædersdal M, Wulf HC. *Artificial daylight photodynamic therapy with “non-inflammatory doses of hexyl aminolevulinate only marginally delays SCC development in UV-exposed hairless mice.* Photochemical and photobiological Sciences 2013;12, 2130-6.
- VI. Togsverd-Bo K, Philipsen PA, Hædersdal M, Wulf HC. *Skin autofluorescence reflects individual seasonal UV exposure, skin photodamage and skin cancer development in organ transplant recipients.* Journal of photochemistry and photobiology: B. 2018;178: 577-583.
- VII. Togsverd-Bo K, Philipsen PA, Hædersdal M, Wulf HC. *Organ transplant recipients express Enhanced skin autofluorescence and pigmentation at skin cancer sites.* Journal of photochemistry and photobiology: B. 2018;188: 1-5.

2 Abbreviations and Definitions

AFL	Ablative fractional laser
AK	Actinic keratoses
ALA	5-aminolevulinic acid
AU	Arbitrary units
BCC	Basal cell carcinoma
CO ₂	Carbon dioxide
Er:YAG	Erbium-doped yttrium aluminum garnet
HAL	Hexyl aminolevulinate
HPV	Human papilloma virus
IQR	Inter-quartile range
KC	Keratinocyte carcinoma, comprises basal cell carcinomas and squamous cell carcinomas
Laser	Light Amplification by the Stimulated Emission of Radiation
logP	Partition coefficients of octanol/water,
LED	Light emitting diode
Light-dose	The total amount of radiant energy delivered per unit area (Irradiance x irradiation time). The unit is J/cm ²
LSR	Local skin response
Lux	The SI unit of illuminance, which is a measure of the intensity of incident light, wavelength-weighted by the luminosity function to correlate with human light brightness perception
MAL	Methyl aminolevulinate
MAZ	Microscopic ablation zone
MED	Minimal erythema dose. UV dose in SED that elicits just perceptible erythema 24 hours after UVR exposure
MW	Molecular weight. The unit is dalton (Da). 1 Da = 1.6605381(73) × 10 ⁻²⁷ kg
nm	Nanometre = 10 ⁻⁹ m

NMSC	Non-melanoma skin cancer
OTR	Solid organ transplant recipient
PPF	Pigment protection factor
PDT	Photodynamic therapy
cPDT	PDT with ALA/MAL cream incubated under occlusion for 3 hours followed by illumination with red light emitted from a broad band or LED light source
dPDT	PDT with ALA/MAL cream incubated without occlusion for 30 minutes followed by 2½ hours daylight exposure at minimum 10,000 lux
PpIX	Protoporphyrin IX
RTR	Renal transplant recipients
ROS	Reactive oxygen species
SCC	Squamous cell carcinoma
SED	Standard erythema dose. 1 SED = 100J/m ² at 298 nm using the CIE erythema action spectrum. It is equivalent to the UVR dose needed to provoke a just perceptible erythema of white skin in the most sensitive of a group of people 24 hours after exposure.
SSR	Simulated solar radiation
UVA	Ultraviolet radiation in the A range (321-400 nm)
UVB	Ultraviolet radiation in the B range (281-320 nm)
UVC	Ultraviolet radiation in the C range (200-280 nm)
UVR	Ultraviolet radiation (200-400 nm)
WLL	Warty like lesions. Dysplastic verrucous lesions

3 Introduction

Solid organ transplantation has since the 1950s evolved from an experimental technique to an integrated treatment modality of end-stage organ failure (Krisl and Doan, 2017; Calne, 2014). Today, nearly 120 000 organ transplants world-wide extend the lives of thousands of patients annually (<http://www.transplant-observatory.org>). During the past decades, improvements in immunosuppressive regimens, graft preservation, surgical techniques and prevention strategies towards infections has significantly increased graft and patient survival leading to a growing population of organ transplant recipients (Kasiske et al., 2010). However, continuous immunosuppressive therapy needed to maintain engraftment is associated with cutaneous adverse effects, especially a high incidence of keratinocyte carcinomas and premalignant actinic keratoses (Euvrard et al., 1993; Zwald and Brown, 2011a).

Dermatologic manifestations after organ transplantation can overall be classified as 1) early events associated with initial heavy immunosuppression and 2) late events related to cumulative effects of immunosuppressive therapy. Shortly after transplantation, a high immunosuppressive load increases risk of bacterial and viral skin infections such as folliculitis, impetigo, cellulitis, herpes and varicella virus reactivation with reported incidence rates in up to 30% of patients (Ulrich et al., 2008). Early drug induced adverse reactions include acneiform eruptions, hypertrichoses, striae distansae, hair loss and gingival hyperplasia, but frequencies are typically reduced when immunosuppressive doses are tapered within the first 3-6 months after transplantation (Sitek et al., 2014). After organ transplantation, patients have an increased susceptibility to viral infections, especially infection with human papilloma virus (HPV). HPV infection are reported to affect up to 50% of transplant recipients and typically present as viral warts on the hands and feet (Piaserico et al., 2014; Sitek et al., 2014). Furthermore, higher prevalence of genital HPV infection and HPV-associated atypia in OTRs compared to matched immunocompetent controls was recently observed in a large study (Larsen et al., 2019). While cutaneous HPV infection has been associated with development of keratinocyte carcinoma in OTR, the association is currently not established (Harwood et al., 2017).

The most important dermatologic effect of long-term immunosuppression is a significantly high incidence of keratinocyte carcinoma, including cutaneous squamous cell carcinoma (SCC) and basal cell carcinoma (BCC) as well as premalignant actinic keratoses and dysplastic verrucous keratoses. Organ transplant recipients (OTRs) have a 65-218 times increased risk of SCC and a 5-10 times increased risk of BCC compared to the background population. The risk of SCC increases with the duration of immunosuppressive therapy from 12 times higher at 5 years after transplantation to 56 – 218 times higher than the background population at 20 – 30 years after transplantation (Krynitz et al., 2013; Madeleine et al., 2017). Indicating a more aggressive growth pattern, SCC nodal metastasis rates are reported from 3.5% to 8% in transplant recipients compared to 0.3-1% in immunocompetent patients (Lindelof et al., 2006; Karia et al., 2013). Correspondingly, SCC-related mortality is reported as high as 10% in OTRs with multiple SCCs (Lindelof et al., 2006) or as 35.3

per 100,000 person-years in OTRs, being more than 10 times higher compared to immunocompetent patients (Garrett et al., 2016;Lanz, 2018). Transplant recipients also possess a substantially elevated risk of premalignant actinic keratoses (AK) and dysplastic verrucous keratoses, which develop at younger age and at higher density compared to immunocompetent patients (Ramsay et al., 2002). AK are important skin changes as they are clear risk indicators for SCC (Bouwes Bavinck et al., 2007). The onset of AK, dysplastic keratoses and KC progress over time from solitary lesions in sun exposed skin into a confluent field of multiple AK, dysplastic keratotic lesions and recurring KC, described as field cancerization ((SLAUGHTER et al., 1953) as shown in Figure 1. Multiple AK and chronically photodamaged skin are established as strong predictors of simple SCC and metastatic SCCs (Lindelof et al., 2005;Wallingford et al., 2015).

In these areas with extensive actinic damage, international guidelines recommend topical field-treatment to reduce both clinical and subclinical dysplasia and potentially lower the risk of SCC development (Lumbang and Stasko, 2011;Hofbauer et al., 2009;Zwald and Brown, 2011b).

Photodynamic therapy (PDT) is among imiquimod, 5-fluoruracil and diclofenac the most investigated topical treatment for AK and field cancerization in OTR (Blomberg et al., 2017;Zwald and Brown, 2011b). Administered with daylight or conventional light emitting diode (LED)-light, PDT is an effective treatment of AK with favourable cosmetic results that especially is suitable for treatment of large skin areas (Braathen et al., 2012). PDT has furthermore shown to be effective to prevent the development of new AK in OTRs with field cancerization and multiple AK (Wulf et al., 2006;Wennberg et al., 2008). However, PDT is hampered by low efficacy in thick, keratotic AK located in acral skin areas (Kaufmann et al., 2008;Tyrrell et al., 2011), as well as lower AK clearance rates are reported in OTRs compared to immunocompetent patients (Dragieva et al., 2004a). The potential of PDT for early prevention of skin dysplasia furthermore remains unclear, leaving the ideal time of treatment initiation yet to be established. As onset and burden of AK and SCC varies widely between transplant recipients (Garrett et al., 2017) objective methods to identify patients with an individual high risk of AK and KC development are warranted. We aimed to increase PDT efficacy for AK clearance, assess the potential of PDT for early AK and KC prevention, and improve objective individual risk assessment for keratinocyte dysplasia, in order to develop individualized AK treatment and prevention for OTRs.

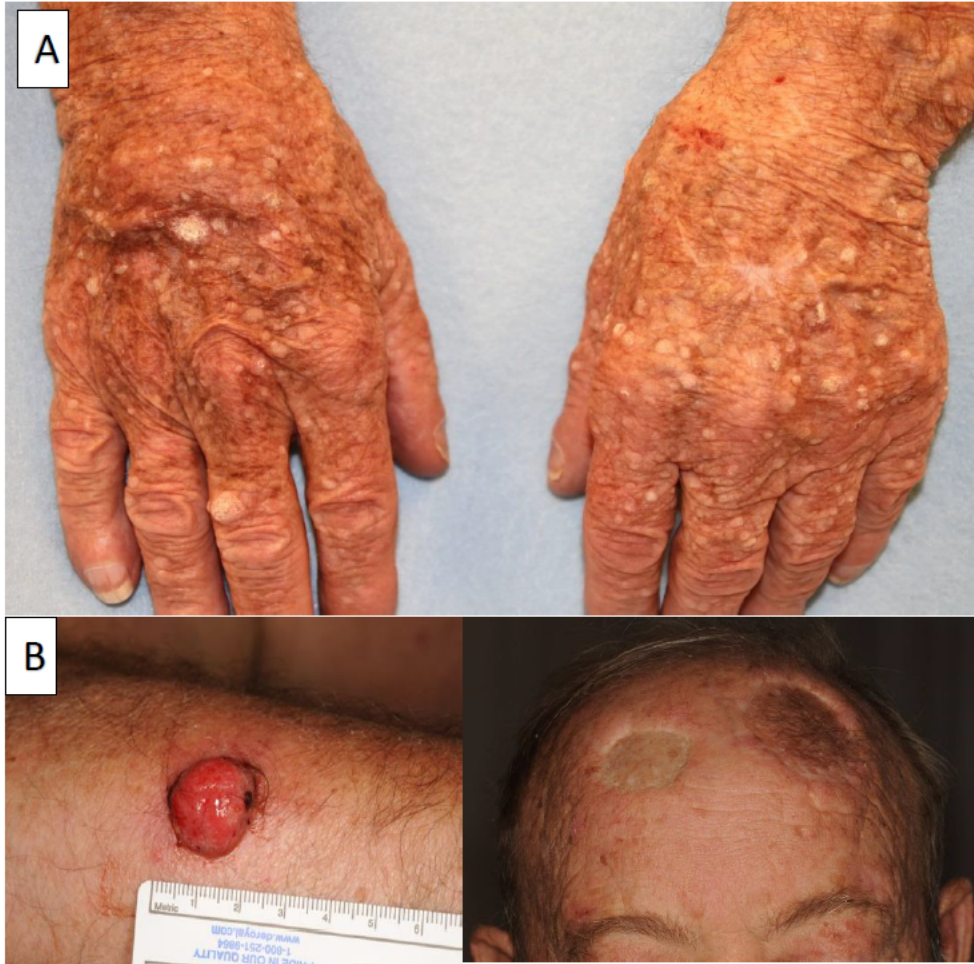

Figure 1: *Cutaneous dysplasia in OTR. A: multiple verrucous keratoses and AKs on the dorsal hands, B: rapidly growing SCC on the dorsal arm, and C: scarring from SCC excision in field-cancerized skin on forehead and scalp.*

3.1 Aim of the Thesis

The aim of the thesis was to investigate ablative fractional laser to improve PDT efficacy for AK in OTRs and to evaluate the effect of PDT for primary prevention of AK. Furthermore, we explored associations between non-invasively measured photodamage and KC in OTRs to identify high-risk patients that could benefit from prophylactic PDT treatments.

The overall objective of the thesis was assessed in three sections:

- I. To assess PDT's efficacy for AK clearance in OTRs, and to investigate the potential of ablative fractional laser in combination with PDT to increase AK clearance. First, we aimed to determine the efficacy of conventional MAL-PDT compared to imiquimod for AK clearance. Second, we attempted to improve the PDT clearance of thin and keratotic AK by combining ablative fractional laser resurfacing prior to conventional and daylight PDT. These points were evaluated in 3 randomized controlled trials in Study I-III.
- II. To explore the potential of PDT for primary prevention of AK in renal transplant recipients and for SCC in a hairless mouse model. In renal transplant recipients, we compared split-side conventional PDT treatment for 5 years with no treatment to prevent first onset of keratinocyte dysplasia in Study IV. In hairless mice, we explored the potential of repeated, artificial daylight PDT with low photosensitizers concentrations to prevent SCC in Study V.
- III. To investigate the potential of non-invasive, objective measurements to determine skin photodamage in OTRs and immunocompetent patients with skin cancer. We assessed associations between KC and UVR exposure and objectively measured photodamage in terms of skin pigmentation, skin autofluorescence, and black-light evaluated solar lentigines in Study VI. Furthermore, we explored differences in non-invasively measured photodamage adjacent to KC in OTRs and immunocompetent patients with KC in Study VII.

4 Background

4.1 Ultraviolet radiation

Exposure to ultraviolet radiation (UVR) is recognized as the main etiologic factor for skin cancer in humans. Terrestrial solar UVR is divided in two main wavelength components, the more carcinogenic UVB (280-320 nm), which mainly damages the epidermis, and the more penetrant UVA (321-400 nm), which reaches into the dermis (WHO, 1992). As stratospheric ozone filters most UVB, terrestrial sunlight consists of >95% UVA and $\leq 5\%$ UVB with the maximum UVB proportion emitted around midday at equator (Wulf and Eriksen, 2010; Lerche et al., 2017).

UVR induce acute and chronic effects on human the skin. Acute effects include erythema, pigmentation in terms of immediate pigment darkening and delayed tanning, thickening of the epidermis, vitamin D synthesis and immunosuppression (WHO, 1992). Chronic effects of UVR exposure are photocarcinogenesis and photodamage. These effects result from direct photon energy absorption by endogenous skin chromophores, such as DNA and melanin or through indirect structural damage mediated by UVR-elicited reactive oxygen species (ROS) (Young, 1997).

4.1.1 Photocarcinogenesis

Photocarcinogenesis is a cascade of UVR-mediated events involving UV-induced DNA damage, cellular mutations and eventually skin cancer development (de Gruijl, 1996; Young, 1990). UVR furthermore induce alterations in transmembrane signal transduction, increases proinflammatory mediators and modulate the immuneresponse, resulting in inflammation and immunosuppression (Berman and Cockrell, 2013; Nishisgori, 2015). These effects all contribute to development of keratinocyte dysplasia.

Determined by DNA's absorption spectrum, UVR-induced DNA damage is wavelength depended as DNA has high absorption in the UVB spectrum and significantly lower in the UVA spectrum. UVB therefore mainly induce direct DNA damage whereas UVA predominantly causes indirect DNA damage mediated by ROS, especially singlet oxygen (de Gruijl, 2000; de Gruijl and Rebel, 2008). Direct DNA damage consist of potentially mutagenic cyclobutane pyrimidine dimers (CPD) and 6,4 pyrimidine-pyrimidone (6,4 Py:Pys) photoproducts, of which CPDs are particularly potent in skin cancer development (de Gruijl et al., 2001). CPDs are furthermore recognized as essential promotor of cytokine-mediated inflammation that clinically present as erythema after UVR exposure. UVA induce indirect DNA damage through ROS causing 8-oxo-deoxyguanosine lesions but also result in CPDs (Halliday et al., 2011). Besides targeting DNA, UVA-induced ROS also damages membrane lipids and proteins, including enzymes involved in DNA repair and thereby attenuate the repair of UV-induced photoproducts (Gueranger et al., 2014a).

If UVR-induced DNA damage is not removed by repair mechanisms such as nucleotide excision repair, replicated CPDs and 6,4 Py:Pys photoproducts can lead to transition type mutation such as

cytosine to thymine (C T) or less frequently CC TT. These specific “UV signature mutations” are especially observed in tumor suppressor genes, particularly p53, in up to 50% of cutaneous SCCs and AK, as well as in photodamaged skin. UVR also induce mutations in other tumor suppressor genes such as p14, p15 and p16 and signature mutations in p53 (Berman and Cockerell, 2013). Keratinocytes harbouring mutations in tumor suppressor genes can, if not eliminated, undergo uncontrolled proliferation and transform into AK and KC.

4.1.2 UV-induced immunosuppression

UVR-induced immunosuppression is an important component in photocarcinogenesis (Kripke, 1984). This was first described by Kripke who showed that UVR suppression of the host’s immune response was required to allow progressive tumor growth (Kripke, 1974). Subsequently, multiple studies describe complex pathways of UVR-induced immunosuppression that modulate the immune response of irradiated skin and in the draining lymph nodes (Hart and Norval, 2018;Byrne, 2008;Ullrich, 2012).

UVR induce local and systemic immunosuppression in terms of suppression of contact hypersensitivity and delayed type hypersensitivity (Kim, 1990). Both UVB and UVA induce immunosuppression, although UVB is significantly more immunosuppressive than UVA (Kim, 1990). However, UVA is due to its large composition in sunlight, increasingly recognized as a large contributor to immunosuppression from daylight exposure (Damian, 2011;Halliday et al., 2011). UVR-induced immunosuppression is initiated mainly in keratinocytes by CPDs and 6,4 Py:Py photoproducts, oxidation of membrane lipids to form platelet activating factor and UV-induced formation of cis-urocanic acid from trans-urocanic acid (Kim, 1990;Hart and Norval, 2018). These mediators stimulate production of inflammatory cytokines, chemokines and activate cyclooxygenase-2 (Shreedhar et al., 1998) that subsequently modulate the effect of Langerhans cells, dendritic cells and mast cells (Vink et al., 1997). Following UVR exposure, Langerhans and dendritic cells migrate from irradiated skin to the draining lymph node to induce production of T regulatory cells (Tregs), which have suppressive function on the antigen response (Schwarz, 2005b;Schwarz et al., 2010). Tregs modulate antigen presenting cells to induce antigen tolerance (Schwarz and Schwarz, 2010), increase production of suppressive cytokines and can suppress the response of effector T cells against dysplastic cells (Lai et al., 2016). Tregs were furthermore found at high concentration in BCCs and in SCCs with more aggressive growth patterns (Lai et al., 2015;Omland et al., 2016). Mast cells, suppressor B cells and Natural Killer T cells are also critical players in modulating the immune response (Ullrich and Byrne, 2012). In conjunction with several complex immune regulatory pathways, these mechanisms result in an antigen-specific immune tolerance towards dysplastic keratinocytes and are crucial for development and growth of skin tumors (Schwarz, 2005a;Hart and Norval, 2018).

4.1.3 Photodamage

Besides photocarcinogenesis, chronic effects of UVR include skin photodamage, or skin photoaging. Photodamaged skin is characterized by dyspigmentation and degenerative changes of vascular and dermal connective tissue structures (Young, 1990). Clinically, it is characterized by wrinkles, skin laxity, telangiectasia, increased fragility and mottled pigmentation consisting of ephelides, solar lentigines and guttate hypomelanosis, shown in Figure 2 (Wulf et al., 2004). Photodamaged skin is an independent risk factor for skin cancer development and shares similar changes in gene expression as observed in cutaneous malignancies (de Gruijl and Voskamp, 2009)

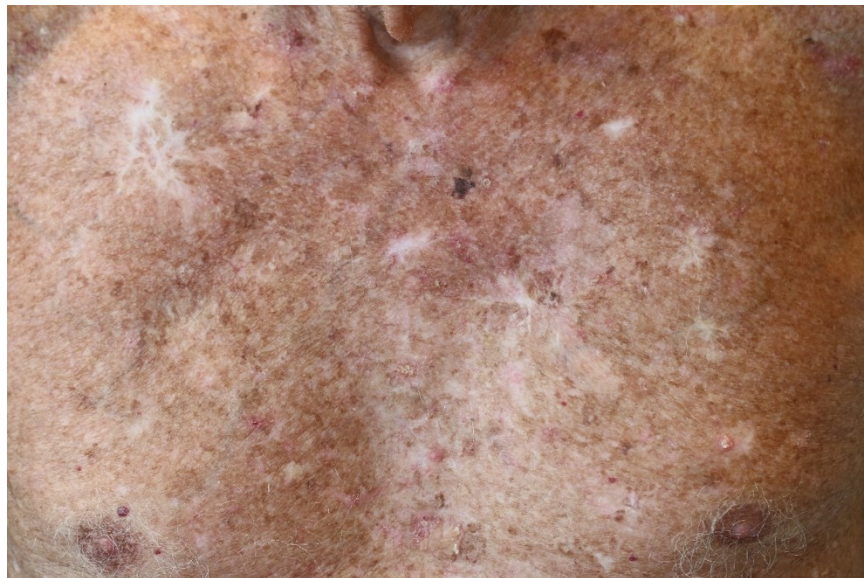

Figure 2: *Severely photodamaged skin characterized by increased pigmentation, solar lentigines, hypomelanosis, AKs and multiple scarring following curettage and cryotherapy of skin dysplasia.*

Dermal photodamage is especially associated with fragmentation of elastin and collagen (type I and III) fibres (Amano, 2016), which comprises the majority dry weight of the dermis. Collagen fibres are in normal skin connected with intermolecular, mature cross-links that provide stability and tensile strength of the skin. In photodamaged skin and intrinsic aged skin, collagen fibres are degraded by enzymatic and non-enzymatic glycosylation processes resulting in increased incomplete collagen cross-links (Monnier et al., 1986). UVR also degrade elastic fibres into accumulating amounts of abnormal elastoid tissue in the superficial dermis, histologically described as solar elastosis (Tewari et al., 2014). These changes are characterized by UVR-induced chronic inflammation with upregulation of matrix-degrading proteases, matrix metalloproteinases (MMPs) that cleave fibrillar collagen and reduce new collagen synthesis (Yarosh et al., 2008).

In chronically UVR exposed skin, mature collagen cross-links are shifted towards a higher content of immature cross-links available for non-invasive measurements (Gillies et al., 2000). Two collagen autofluorescence bands with peak absorption at 330-340 nm and 360-370 nm excitation are described to originate from predominantly collagen-crosslink products (Kollias et al., 1998; Takema et al., 1997). Furthermore, an autofluorescence band at 440 nm excitation has been identified as reflecting elastin and collagen. Linkage between skin autofluorescence and photodamage was investigated in studies that found higher collagen autofluorescence with increasing patient age and near basal cell carcinomas (Na et al., 2001b; Na et al., 2001a; Yamauchi et al., 1991).

Pigmentary changes are major components in photodamaged skin. Repeated UVR exposure stimulate melanosome formation leading to an increase in the number of melanocytes compared with unirradiated skin as well as higher density of melanophages and epidermal melanin (Fisher et al, 2002; Bilac et al, 2014). The pigmentary alterations in photodamaged skin include hypomelanosis and hypermelanoses, such as solar lentigines (Young, 1990). Solar lentigines are highly associated with chronic cumulative sun exposure, high intermittent UVR exposure and AK, KC and cutaneous malignant melanoma in fair skinned patients (Bastiaens et al., 2004; Dessinioti et al., 2011; Idorn et al., 2014; Thieden et al., 2005a). Broad-band UV light or “black light” at 315-400 nm enhance the definition of pigmentary changes and depigmented and pigmented lesions are effectively visualized by fluorescence photographs (Kollias et al., 1997). Black light entering the dermis stimulate emission of collagen fluorescence of which some is returned toward the skin surface. However, the emitted fluorescence is attenuated by haemoglobin and epidermal melanin that appear as dark areas in black light (Gilchrest et al., 1977). Hence, fluorescent black light photographs is effective to visualize lentigines and dark spots and is has been linked to sun damage and a high UVR exposure pattern in both adolescents and melanoma patients (Idorn et al., 2014; Gamble et al., 2012).

Determined by both genetic susceptibility and exposure to environmental hazards such as UVR exposure, the extent of skin photodamage implies large intra-individual variations and consequently determines the frequency of skin cancer surveillance. Furthermore, the magnitude of skin photodamage may present differently in OTRs compared with immunocompetent patients.

4.2 Photodynamic therapy

Topical photodynamic therapy with precursors of the endogenous photosensitizer Protoporphyrin IX (PpIX) is a well-established, effective treatment for AKs, in situ SCCs and superficial BCCs.

4.2.1 Mechanism of action

PDT involves the combination of a photosensitizer, oxygen and light to initiate a photochemical reaction (Henderson and Dougherty, 1992). When a photosensitizer absorbs light of appropriate wavelengths, an electron is transferred to a higher energy orbital and the photosensitizer enters the excited

singlet state (Figure 3) (Redmond, 2008). As the singlet state is highly unstable, the photosensitizer either emits fluorescence or heat or undergoes intersystem crossing to form a more stable excited triplet state (Redmond, 2008). From the triplet state, PpIX can i) decay to the ground state, ii) react directly with molecules to form ROS, (type I reaction) or iii) react directly with tissue oxygen to form singlet oxygen (type II reaction) (Moan and Juzeniene, 2008). Singlet oxygen is considered the most important mediator of PDT-induced damage although ROS induces significant tissue damage. The therapeutic effect results from a combination of direct cell death induced by oxidative products, microvascular damage and an elicited immune response (Garg et al., 2010;Korbelik, 2008). The microvascular damage, and inflammatory response are both considered contributors to treatment of the dysplastic lesions and may influence long-term outcome in solid tumors (Agostinis et al., 2011;Mroz et al., 2010).

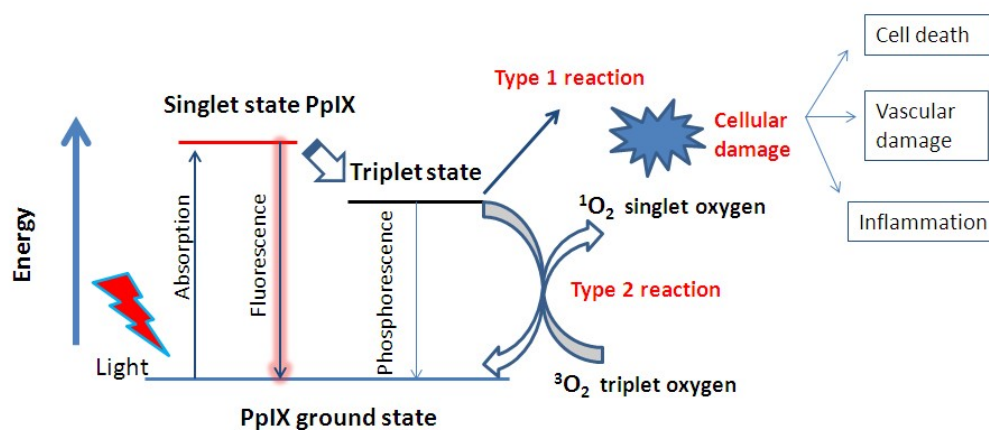


Figure 3: *The photodynamic process. Modified from (Agostinis et al., 2011).*

4.2.2 Porphyrin photosensitizers

PDT with porphyrin precursors is based on exogeneous delivery of 5-aminolevulinic acid in heme synthesis that intracellularly accumulate into the photoactive Protoporphyrin IX (PpIX) (Kennedy et al., 1990;Pottier et al., 1986). Three PpIX precursors are currently commercially available: 5-aminolevulinic acid (ALA) and the esters, methyl aminolevulinate (MAL) and hexyl aminolevulinate (HAL). PDT with ALA and MAL is approved for treatment of thin-moderately thick AK, SCC in situ as well as superficial and low-risk nodular BCCs (www.ema.europa.eu/human). HAL is approved for intra-vesical fluorescence diagnostic of bladder dysplasia.

ALA is a precursor of PpIX in synthesis of heme with insertion of iron into PpIX by the enzyme ferrochelatase as the final step (Figure 4). Heme is synthesized in the inner mitochondria membrane

and cytosol of all nucleated cells, and tightly controlled by negative feedback. By exogenous supply of excess ALA, feedback mechanisms are bypassed and PpIX accumulate in the tissue (Kennedy and Pottier, 1992). The amount of accumulated PpIX depends primarily on intracellular ALA concentration, but also on enzymatic activity in heme synthesis and intracellular iron supply (Kennedy et al., 1990). Due to an increased cellular porphyrin metabolism but lower intracellular iron content, PpIX more readily accumulate in dysplastic than in normal cells (Krieg et al., 2002).

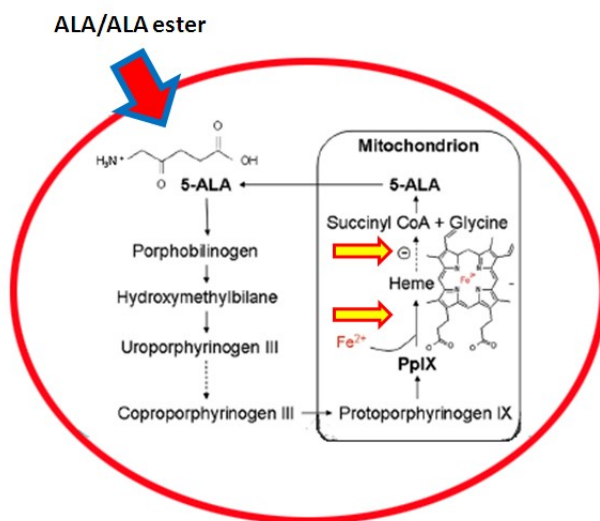


Figure 4: Intracellular ALA and heme metabolism. Exogeneous application of ALA (red arrow) bypass the negative feedback of ALA synthase (top yellow arrow) and slow conversion of PpIX to heme (bottom yellow arrow), leading to PpIX accumulation

Topical delivered PS must penetrate the stratum corneum in order to reach the target tissue. Stratum corneum (SC) is the main barrier to topical drugs and consists of layers of keratin-filled corneocytes embedded in lipids, resulting in a highly lipophilic, acidic environment (Flynn, 1997). Hence, small, lipophilic molecules can easier penetrate the SC than hydrophilic molecules. ALA is a small, hydrophilic molecule (168 Da, logP -1.52) and a zwitterion at physiological pH with suboptimal penetration over intact stratum corneum (Juzeniene et al., 2002; Fotinos et al., 2006). More recently, nano-emulsion with ALA was developed to improve ALA stability and SC penetration (Szeimies et al., 2010a; Szeimies et al., 2010b).

To enhance bioavailability and selectivity of PpIX accumulation in dysplastic tissue, the methyl ester of ALA, methyl aminolevulinate (MAL) was introduced. MAL is slightly larger (182 Da) and slightly less hydrophilic (logP -0.94) than ALA (Uehlinger et al., 2000; Peng et al., 1996). While ALA induces higher PpIX intensities, MAL results in a more selective PpIX accumulation in diseased skin with a higher lesion/normal tissue concentration ratio than ALA (Fritsch et al., 1998; Wiegell and

Wulf, 2006). Following introduction of MAL, different lipophilic ALA esters were investigated for topical PDT (Fotinos et al., 2006). Of these, the hexyl ester of ALA, hexyl aminolevulinate (HAL) was licensed for intravesical PpIX fluorescence detection of bladder dysplasia (Mostafid and Bunce, 2009). In human skin, HAL-PDT has been experimentally investigated for acne and treatment of AK (Neittaanmaki-Perttu et al., 2017). HAL induces significantly more PpIX fluorescence than equivalent concentrations of ALA and MAL but showed similar tissue distribution in normal skin (Togsverd-Bo et al., 2012c; Juzeniene et al., 2006). Although HAL is significantly more lipophilic (logP 1.84) than MAL, the larger molecule size (252 Da) may prolong SC penetration.

4.2.3 Light sources

Light sources for PDT must match PpIX's absorption spectrum and sufficiently penetrate the skin to photoactivate PpIX within the target lesions (Henderson and Dougherty, 1992). PpIX has a maximum absorption band in the blue light spectrum (Soret band, 405-415 nm) and weaker absorption in green (506-540 nm), yellow (572-582 nm) and red (628-635 nm) wave-bands. Although PpIX absorption is substantially higher at 405 nm, blue light poorly penetrate into the dermis whereas red light has deeper skin penetration and can drive PDT reactions down to 2 mm (Juzenas et al., 2001). Hence, studies comparing therapeutic response to PDT found illumination with red light more effective than green light to induce apoptosis and for treatment of SCC in situ (Braathen et al., 2007; Morton et al., 2000).

A range of light sources are applicable for PDT, including broad-band lamps, diode lamps, flash lamps and lasers, emitting either continuous wave or pulsed wave light. Commercial lamps for PDT are currently available as fluorescent lamps in the blue light spectrum and in the red light spectrum by light emitting diode lamps (LED) with a 630 nm/635 nm emission peak (Morton et al., 2012a). Energy based devices such as intense pulsed light systems (IPL) and long-pulsed dye laser are also used for PpIX photoactivation in PDT. These light sources use high-energy radiation to deliver the desired fluence in few pulses and are frequently combined with PDT for additional photorejuvenating effects (Brancaleon and Moseley, 2002; Morton et al., 2012b).

In conventional PDT (cPDT), ALA or MAL incubate under light occlusive dressing for usually 3 hours followed by illumination with certified lamps in the blue or red light spectrum (Christensen et al., 2010). During incubation, large amounts of PpIX accumulate in the skin and the subsequent rapid photoactivation during illumination is painful in many patients (Wiegell et al., 2008b; Halldin et al., 2011). To alleviate pain sensations and simplify the PDT procedure, Wiegell and Wulf introduced daylight PDT (dPDT) in 2008 (Wiegell et al., 2008a). The visible daylight spectrum ranges from 400-760 nm, covering all PpIX absorption peaks. In dPDT, continuous exposure to daylight during MAL/ALA incubation result in a continuous photoactivation of PpIX and thereby replaces illumination with conventional light sources. The continuous photoactivation of small amounts of synthesized PpIX significantly reduce patients pain sensation and increase tolerability with similar efficacy as

conventional PDT (Wiegell et al., 2008a). dPDT can be performed in dry weather at light intensities above 8 J/cm^2 or 10.000 lux and temperatures above 10 degrees celsius (Wiegell et al., 2013). However, as violet, blue and cyan light (380-495 nm) mainly contribute (85%) to PpIX photobleaching compared to the deeper penetrating orange-red light (3%), dPDT is only licensed for AK treatment (Wiegell et al., 2012). More recently, artificial light sources with emission spectra similar to natural daylight may apt as effective alternatives when natural daylight exposure is not possible due to weather conditions (O’Gorman et al., 2016;Lerche et al., 2016).

4.2.4 Physical pretreatment of AKs

Physical pretreatment to reduce crusts/keratoses of moderate or keratotic lesions and facilitate ALA/MAL skin penetration, is an integrated part of the PDT procedure in Europe (Morton et al., 2012a). Superficial curettage is a common technique (Christensen et al., 2010), but other methods such as microdermabrasion, microneedling and ablative fractional lasers are increasingly used to disrupt the stratum corneum barrier and increase PpIX accumulation (Gerritsen et al., 2009;Haedersdal et al., 2016). Chemical pretreatment with keratolytic agents or topical drugs that enzymatic increase PpIX formation have also been introduced to increase PpIX formation and PDT efficacy (Nissen et al., 2016;Gerritsen et al., 2009).

During the past 10 years, ablative fractional lasers have emerged as a novel treatment modality to enhance the transdermal delivery of topical drugs including MAL and ALA (Haedersdal et al., 2010;Forster et al., 2010). Compared with alternative physical pretreatments, these devices induce a faster and enhanced amount of PpIX accumulation in the skin (Haedersdal et al., 2016).

4.3 Ablative fractional lasers and PDT

Laser is an acronym for Light Amplification by Stimulated Emission of Radiation. A laser consists of an excited medium placed between two mirrors that pass light back and forth, increasing the light intensity by stimulated emission. As a result, lasers emit intense, collimated and coherent light at one wavelength. Lasers are currently available in a range from the UV spectrum to the far infrared spectrum, targeting different skin chromophores such as haemoglobin, melanin or water by selected photothermolysis. The concept selected photothermolysis describes focal destruction of target structures following laser exposure at specific wavelength, energy and pulse duration that matches the target chromophore (Anderson and Parrish, 1983). Depending on the target chromophore, lasers can produce different effects on the skin such as thermal denaturation, changes in chemical structures or vaporization and tissue ablation (Anderson, 2007). Later, fractional photothermolysis was introduced as a technique that generate thousands of microscopic treatment zones of thermal injury, while leaving the remaining skin intact (Manstein et al., 2004). Fractional lasers can leave non-ablative or ablative interaction within the skin. Available ablative lasers are carbon dioxide (CO_2 , 10 600 nm), erbium:yttrium

aluminium garnet (Er:YAG, 2940 nm) lasers and yttrium scandium gallium garnet laser (YSGG, 2970 nm), which emit wavelengths that are strongly absorbed by water and rapidly vaporize the tissue (Erlendsson et al., 2014).

Ablative fractional lasers (AFL) create a grid of vertical channels or microscopic ablation zones (MAZ) that are lined with a thin border of coagulated tissue as illustrated in Figure 5. AFL impact on the skin can be adjusted by MAZ depth and MAZ density. The MAZ depth is characterized by ablation depth into the skin and can be modulated by the applied total pulse energy (Taudorf et al., 2014a). MAZ density represent the fraction of the ablated skin surface area and is determined by laser spot size and number of MAZ channels per unit skin area (Haedersdal et al., 2016). As each laser channel disrupts the epidermal skin barrier, AFL is highly effective to increase cutaneous drug delivery (Haedersdal et al., 2016). AFL-assisted drug delivery was introduced with topically applied MAL and ALA and showed significantly enhanced PpIX accumulation in laser-treated skin compared with non-treated skin (Haedersdal et al., 2011;Forster et al., 2010).

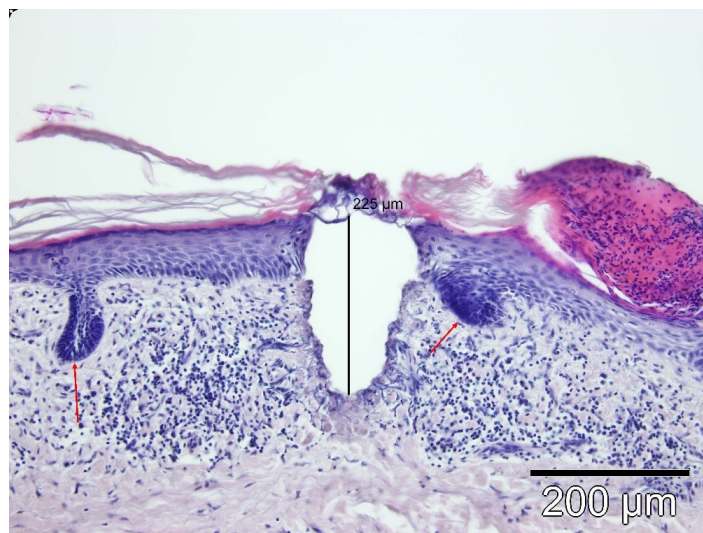


Figure 5: *Cross section of haematoxylin-eosin stained human, field-cancerized skin exposed to CO₂ ablative fractional laser 40mJ/mbeam.*

Later, studies have explored AFL-assisted delivery of numerous topical drugs such as steroids, antifungal and chemotherapeutic agents (Haedersdal et al., 2016).

To achieve a specific tissue response, MAZ dimensions and density can be independently adjusted according to skin characteristics of the treatment area and target lesions. The influence of laser settings on MAL penetration and PpIX biodistribution has been investigated in clinical and preclinical settings (Haak et al., 2016;Haedersdal et al., 2010;Haedersdal et al., 2016). These studies suggest that laser densities up to 5% are optimal to intensify PpIX accumulation in normal skin with no

further gain at increased laser densities (Haak et al; 2016). In terms of ablation depths, dermal PpIX fluorescence did not increase with deeper laser channel depth in porcine skin (Haak et al., 2012;Haak et al., 2016). In a recent comparison of different physical pretreatment techniques, AFL substantially increased PpIX fluorescence in comparison with non-ablative fractional laser, microneedling, curettage and microdermabrasion (Bay et al., 2017).

AFL in combination with PDT (AFL-PDT) has in clinical studies been investigated to enhance the efficacy of PDT for AK clearance rate with improved photorejuvenation compared with conventional PDT (Choi, 2015;Ko, 2014;Togsverd-Bo et al., 2012a;Togsverd-Bo et al., 2015;Wenande, 2019). These studies find a higher AK clearance rates and improved photorejuvenation by AFL-PDT but also increased local skin reactions compared with cPDT (Togsverd-Bo et al., 2012b;Wenande, 2019). For BCCs, AFL-PDT with MAL resulted in high efficacy for small and low-risk nodular tumors yet similar clearance as cPDT for BCCs in difficult-to-treat areas (Haak et al., 2014;Choi et al., 2016;Lippert et al., 2013).

4.4 Organ transplant recipients and keratinocyte dysplasia

UVR exposure and individual susceptibility to UVR are major etiologic factors for KC development in both immunocompetent and immunosuppressed patients (Ulrich C, 2004). However, long-term immunosuppression reduces immune surveillance, potentiate the carcinogenic effects of UVR and promote persistent HPV infection that all significantly contribute to AK and KC development in OTR.

4.4.1 Incidence of KC and AK management

As initially described, OTRs have significantly higher incidence rates of SCC and BCC compared to immunocompetent patients, including a higher SCC:BCC ratio (Krynitz et al., 2015;Euvrard et al., 1997;Jensen et al., 2010). These epidemiological studies find incidence rates for SCC between 12-37 times higher at 5-10 years after transplantation and up to 218 times higher at 20 years after transplantation, compared to the background population (Madeleine et al., 2017;Garrett et al., 2017;Euvrard et al., 1997). As KC risk increases with time after transplantation, cumulated incidences report that 13%-17% of liver/kidney transplants, and 33%-42% of heart/lung were diagnosed with SCC at 10 years after transplantation (Madeleine et al., 2017). By 20-30 years after renal transplantation, incidence had increased so 65%-75% of patients were diagnosed with SCC and 46%-64% of patients with BCC (Krynitz et al., 2013).

As with KC, OTRs usually develop AK at younger age and in multiple numbers compared to immunocompetent patients (Ramsay et al., 2007). In conjunction, individual AK lesions may hold a higher potential for transformation into invasive SCC (Werner et al., 2013). AK are important risk indicators of SCC, especially when they appear as confluent lesions as a sign of actinic field cancerization (Bouwes Bavinck et al., 2007). Hence, the risk of SCC especially occur in chronically

sunexposed skin (Lindelof et al., 2005) and in areas with actinic field cancerization (Bouwes Bavinck et al., 2007;Lindelof et al., 2006). Underscoring this, a UK study reported that 73% of SCC observed developed within actinic field areas (Wallingford et al., 2015).

Treatment of AK in actinic field cancerized skin is preferentially performed with field directed treatment such as PDT, imiquimod, 5-FU (alone and in combination with salicylic acid), diclofenac and ingenol mebutate. While lesion-directed interventions such as cryotherapy and curettage treat individual AK, field treatments aim to clear visible AK as well as subclinical dysplastic lesions (Vatve et al., 2007;Szeimies et al., 2012;Figueras, I et al., 2017).

Although the effect of topical antineoplastic drugs has been extensively assessed in immunocompetent patients, topical therapies such as diclofenac and 5-fluoruracil (5-FU) have been investigated in few clinical trials OTRs (Perrett et al., 2007;Ulrich et al., 2010), or case reports (Muhlstadt, 2016;Jambusaria-Pahlajani et al., 2016). However, OTRs may respond to AK treatments with lower efficacy and shorter lasting effect compared to immunocompetent patients (Dragieva et al., 2004b).

4.4.2 Immunosuppression

The immune system has important functions in preventing development and progression of skin cancer. Iatrogen immunosuppression impair antigen presenting cells surveillance and response towards neoplastic cells and thereby contribute to development and growth of KCs (Krisl and Doan, 2017). Several studies support the fact that both intensity and duration of immunosuppression influence the risk of KC development. Hence, patients receiving thoracic organ transplantation (heart and lung) have higher KC incidence than abdominal organ transplant (renal, pancreas and liver) recipients (Garrett et al., 2017;Collett et al., 2010). Direct procarcinogenic effects have also been identified in specific immunosuppressive drugs that may promote or enhance photocarcinogenesis (Dziunycz et al., 2014;Karran, 2006). Appendix 1 provides an overview of immunosuppressive drugs, mechanism of action and potential effects on skin carcinogenesis. A new study shows a decrease in KC risk with increasing HLA antigen mismatch, suggesting that chronic exposure to mismatch alloantigens may stimulate tumor surveillance and protect against KC development (Gao et al., 2019).

Immunosuppressive therapy ensures organ engraftment and usually includes therapy with a calcineurin inhibitor (CNI, tacrolimus or cyclosporine), an antimetabolite (azathioprine and mycophenolic acids) and possibly, corticosteroids (Kasiske et al., 2010). The introduction of tacrolimus and mycophenolate mofetil (MMF) have to a large extent replaced cyclosporin and azathioprine respectively, due to higher tolerability, fewer acute graft rejections and lower risk of cutaneous malignancy (Coghill et al., 2016). Whereas cyclosporine and azathioprine have shown to inhibit DNA repair following UVR exposure (Dziunycz et al., 2014;Gueranger et al., 2014b;Ming et al., 2015), the pro-carcinogenic effects are unestablished for tacrolimus and MMF (Madeleine et al., 2017). Among the immunosuppressive drugs, azathioprine (AZA) has been identified to accelerate photocarcinogenesis through increasing UVA photosensitivity (Perrett et al., 2008). When AZA is metabolized to 6-thioguanine it is incorporated into

DNA guanine where it becomes a strong UVA chromophore. Upon UVA absorption, 6-thioguanine generate ROS that induce hazardous DNA and protein oxidation including DNA repair proteomes, thereby increasing UVR mutagenicity (Karran, 2006;Attard and Karran, 2012). Consequently, AZA therapy independently is associated with a 2-3-fold increased risk of SCC and a similar enhanced risk of multiple SCCs compared with alternative immunosuppression (Wisgerhof et al., 2010;Ingvar et al., 2010). In contrast, MMF was associated with a lower risk of SCCs than AZA-treated patients (Coghill et al., 2016). The newer mammalian target of rapamycin (mTOR) inhibitors, sirolimus and everolimus may have anticarcinogenic effects and switching from CNI to mTOR have shown to decrease patients' risk of subsequent SCC (Euvrard et al., 2012).

4.4.3 Other risk factors in OTR

Besides immunosuppressive treatment, KC development is associated with a number of intrinsic risk factors such as male sex, age, Fitzpatrick skin phototype I-II, patient age, smoking, painful sunburns and time after organ transplantation (Gogia et al., 2013;Zwald and Brown, 2011a;Proby et al., 2009). Age above 50 years at the time of transplantation is significantly correlated with KC development within the first 5 years of transplantation and a general higher incidence of SCC (Bouwes Bavinck et al., 2007). In several studies, AK and keratotic skin lesions have been identified as the strongest predictive risk factor for SCC in OTR, and a weaker association with BCC (Wisgerhof et al., 2010;Proby et al., 2009;Madeleine et al., 2017;Bouwes Bavinck et al., 2007). The risk of SCC increased with a higher number of keratotic lesions, which also were associated with increasing patient age.

Malignancies presenting in OTRs are often associated with oncogenic viruses, such as post-transplant lymphoproliferative disorders (Epstein-Barr virus) and Kaposi sarcoma (human herpes virus 8). Hence, the oncogenic potential of HPV infection for SCCs/AKs in OTRs has been extensively investigated as beta-type PV is detected in >90% of SCCs in patients with epidermodysplasia verruciformis. Expression of betaPV types E6 and E7 deregulate cellular defence mechanisms, resulting in a higher susceptibility for malignant transformation following UVR exposure suggesting a procarcinogenic effect (Dang et al., 2006). Although betaPV is detected in >80% of patients with normal skin, immunosuppression is associated with increased viral load, multiplicity of HPV subtypes and seropositivity. In conversion, other studies studies have also found no or very low HPV transcriptional activity in SCCs (Arron et al., 2011), which suggest that HPV is involved only in SCC initiation. This in accordance with the observation that viral load is higher in AK compared with invasive SCCs (Quint et al., 2015). Unlike the clear oncogenic role of selected mucosal alphaPV types for anogenital carcinomas, the association between HPV and SCC is supportive but not conclusive (Harwood et al., 2017).

5 Methods

5.1 PDT treatments

PDT treatments were applied for treatment of AK grade I-III in Study I-III in OTRs, for prevention of AK in renal transplant recipients in Study IV, and for SCC prevention in hairless mice in Study V as illustrated in Table 1. Photosensitizers included 20% MAL cream (Metvix 16% cream, Galderma, France) and HAL cream in ultra-low concentrations at 0.1%, 0.05% and 0.02% HAL. For all PDT treatments, MAL and HAL were applied to the entire study area at 0.5 mm thickness.

Study	Subjects	Photosensitizer	Pretreatment	Light source
I	<i>Aim: To compare AK clearance, skin reactions, safety and patient preference of cPDT vs. imiquimod</i>			
	OTR Intra-individual	MAL 20%	Curettage	LED 37 J/cm ²
II	<i>Aim: To assess and compare AK clearance, skin reactions, PpIX fluorescence and cosmetic outcome of cPDT, dPDT, AFL-dPDT and AFL alone</i>			
	OTR Intra-individual	MAL 20%	1) Curettage 2) Er: YAG 2940 nm 2.3 mJ/pulse, 1.15W, 0.05 ms, 2.4%	Daylight 2h ≥8 J/cm ² LED 37 J/cm ²
III	<i>Aim: To assess and compare efficacy of AFL+cPDT vs AFL alone for keratotic AKs and WLL on the dorsal hands</i>			
	OTR Intra-individual	MAL 20%	Lesion: 140-160 mJ/pulse, 6.25 ms, Field: 40-60 mJ/pulse, 2.06 ms, 5.2%	LED 37 J/cm ²
IV	<i>Aim: To explore the effect of repeated cPDT in normal skin for primary prevention of AK and KC in renal transplant recipients</i>			
	RTR Intra-individual	MAL 20%	None	LED 37 J/cm ²
V	<i>Aim: To investigate the effect of repeated artificial dPDT with low-concentration HAL for primary prevention of SCC in UVR exposed hairless mice</i>			
	Hairless mice	HAL 0.1%, 0.05% 0.02%	None	Artificial daylight ~ 6 J/cm ²

Table 1: Overview of PDT procedures in studies I-V. Red LED light (peak 630 nm) was delivered at 68 mW/cm² irradiance.

cPDT and dPDT were performed according to international procedural guidelines (Wiegell et al., 2012; Morton et al., 2012a) and treatment areas shielded from daylight for 24 hours. Artificial daylight in Study V was emitted from 4 xenon light bulbs with a spectral output that matched the daylight

spectrum within PpIX's absorption spectrum (Wiegell et al., 2011). The area under the PpIX weighted artificial daylight curve was similar to the area under the PpIX-weighted daylight curve. The intensity of artificial daylight dose was consecutively monitored with a luxmeter to secure a constant dose of 8000 lux (3.7 mW/cm²), corresponding to a dose of 6 J/cm².

5.2 Clinical evaluations

AK were clinically evaluated at baseline and at follow up visits in Study I-IV. Each lesion was graded by level of thickness according to Olsen into grades I-III: I, thin (slightly palpable AK, more easily felt than seen); II, moderate (moderately thick AK, easily felt) and III, keratotic (very thick or obvious AK) (Olsen et al., 1991). Treatment efficacy was evaluated in Study I-III as complete lesion response (CR) rate, defined as the number of AK with complete response divided by the total number of AK treated within each intervention area of each patient. AK complete response was assessed as disappearance of the lesion, visually and by palpation although mild erythema might remain.

Perceived pain and local skin responses in relation with PDT, AFL and IMIQ treatment were recorded in Study I, II and IV. Patient graded pain response on a numerical rating score with 0 being no pain and 10 being worst imaginable pain. Short-term inflammatory local skin responses (LSR) were assessed as overall severity (Study IV) or by erythema, edema, crusts and pustules (Study I-II) and graded on a categorical 4-point scale. Long-term skin responses were evaluated as cosmetic outcome and as pigmentary changes or scars.

5.3 AFL treatment

In Study II, AFL treatments were performed with a low-powered ablative fractional 2,940 nm Er:YAG laser prototype (P.L.E.A.S.E. Professional, Pantec Biosolutions AG, Lichtenstein) with a fixed spot size of 225 μ m. Immediately after a superficial curettage, the entire treatment area was exposed AFL at 2.3 mJ/pulse, 1.15W, 50 μ s pulse duration, two stacked pulses and 2.4% density. The histologic impact of these settings with the same device showed superficial MAZ at approximately 50 μ m from the SC (Taudorf et al., 2014b).

In Study III, AFL was performed with an ablative fractional 10,600 nm CO₂ laser (Lutronic eCO₂) 30W and 120 μ m spot size. To facilitate MAL delivery in hyperkeratotic lesions, AFL was performed at higher laser settings than in Study II. Furthermore, pulse energy, pulse duration and laser density were adjusted according to skin atrophy (non-atrophic/atrophic). AFL intervention was delivered in two passes; a lesion-targeted treatment and field-directed treatment. First, grade II-III AK and warty like lesions (WLL) received targeted AFL intervention as 160 mJ/pulse, 625 μ s pulse duration and 5.3% coverage (non-atrophic skin); or 140 mJ/pulse, 565 μ s pulse duration and 5.2% coverage (atrophic skin). Subsequently, a second field-directed pass was delivered at 60mJ/pulse, 206 μ s pulse duration and 5.2% coverage (non-atrophic skin); or 40mJ/pulse, 132 μ s pulse duration and 4.3% coverage (atrophic skin)

(Table 1). In normal pig skin, exposure to 10,600 nm ablative fractional 10,600 nm laser applied at a pulse energy of 100mJ and 50 mJ resulted in ablation depths of 349 μm and 130 μm , respectively (Shin et al., 2014).

5.4 Protoporphyrin IX fluorescence

PpIX fluorescence is an established method to estimate the amount of accumulated PpIX or photobleached PpIX following PDT treatment. In Study II and V, skin surface PpIX fluorescence was calculated from PpIX fluorescence photographs taken with a fluorescence imaging system Medeikonos PDD/PDT (Medeikonos AB, Gothenburg, Sweden). PpIX was excited by light with a wavelength of 365 nm - 405 nm generated by filtered mercury lamps at a total light intensity of 0.5 mW/cm² for 4 seconds. PpIX fluorescence images were recorded in a 10x10 cm area by a charged coupled device (CCD) camera at 512x512-pixel resolution, equipped with a red long pass filter that allowed fluorescence of 610-715 nm to pass (Wiegell and Wulf, 2006). PpIX fluorescence was calculated from the images using a computer program (MatLab[®] 7.2.0.232, Mathworks, Natick, MA, USA). Each image was calibrated using a fluorescence standard (Bioscience, Denmark). In each fluorescence image, we defined PpIX fluorescence as pixels having a value of 2500 more than the background image.

PpIX fluorescence in arbitrary units (AU) was then calculated as the mean pixel value (arbitrary unites, AU) of the treatment area:

$$PpIX_{fluorescence} = \frac{(A - B)C}{D}$$

A = mean pixel value in the treatment area with fluorescence above 2500 (AU)

B = mean pixel value in the treatment area prior to MAL/HAL application (background picture)

C = number of pixels with fluorescence above 2500 (AU)

D = total number of pixels in the entire treatment area

5.5 Non-invasive measurements of skin photodamage

Skin photodamage was in Study VI-VII objectively evaluated by skin autofluorescence, skin pigmentation, and black-light assessed solar lentigines as indicators of collagen fibre degeneration, repetitive UVR exposure and accumulated UVR exposure, respectively. Skin autofluorescence and skin pigmentation were obtained at standardized body sites. The predetermined sites were: right lateral upper arm, back of right shoulder, manubrium sternum and right buttock in Study VI-VII including glabella in Study VI, and immediately adjacent to new KC in Study VII.

5.5.1 Skin autofluorescence

Skin autofluorescence was non-invasively measured with two devices having maximum emission at 370nm (F370) and 430nm (F430) (Chromo-light, Denmark). The devices detected filtered fluorescence at wavelengths above 395 nm for F370 (Wratten 2A LP-filter, Eastman Kodak Company, NY, USA), and at wavelengths above 494 nm for F430 (Wratten LP-filter 8, Eastman Kodak Company, NY, USA). Fluorescence values were given in AU. As melanin and haemoglobin have overlapping absorption spectra with collagen fibres (Anderson and Parrish, 1981), autofluorescence values were corrected for redness and pigmentation measured by skin reflectance.

5.5.2 Skin pigmentation

Skin reflectance measurements (Optimize Scientific Model, Chromo-light, Denmark) quantified skin redness and pigmentation percentages and calculates patients' objective skin phototype expressed as pigment protection factor (PPF). PPF represents the individual UVR sensitivity at a specific body site and equates the SED dose required to elicit just perceptible erythema, corresponding to the minimal erythema dose (MED) (Wulf HC 1986, US patent). The PPF measured at unexposed buttock skin express the constitutive skin type (C-PPF), whereas PPF at other body locations express facultative pigmentation (F-PPF). Hence, the minimum F-PPF values during winter indicate a person's UVR-induced pigmentation acquired earlier in life and increase in F-PPF during a summer period as a measure of recent UVR exposure (Thieden et al., 2006).

5.5.3 Black light evaluated solar lentigines

Fluorescent UVA light or black light (315-400 nm) enhances visualization of solar lentigines, ephelides and macular hypopigmentation, which are clinical characteristics in photodamaged skin. In Study VI-VII, standardized black light photographs were obtained using a UVA light source at 367 nm maximum emission (TL08 Philips, Netherlands) to quantify density of solar lentigines. Digital photographs of patients' upper back and shoulders were captured at standardized light and magnification in dimmed light. The density of lentigines, defined as larger, irregular dark spots at the back of the shoulders, were graded by a blinded assessor on a categorical 6-point clinical scale (Idorn et al., 2014).

5.6 Personal electronic UVR dosimeters and sun exposure diaries

Sun exposure behaviour in OTR were assessed with personal UVR dosimeters and sun exposure diaries in Study VI. The personal electronic UVR dosimeters measured UVR doses in SED, stored with a time stamp (Thieden et al; 2001). The dosimeter comprises a sensor, an amplifier and a logger placed in a housing with a digital watch. The sensor is a silicon carbide photodiode with a dielectric filter JECF1-IDE (Laser Components, Olching, Germany) with a sensitivity range of 200-400 nm. The sensor has a

cosine response with a spectral response similar to the erythema action spectrum. The logger controls the sensor and measures every 5 seconds, storing the average of the measurements every 5 minutes. The dosimeter measurement range is 0.07-47.81 SED per hour. The dosimeters were calibrated against a double-grating spectroradiometer DM 150 (Bentham, Reading, UK) using the Sun as light source. Patients wore the dosimeters as wristwatches outdoors between 7AM to 7PM. A sun exposure diary was used to connect the measured UVR doses with corresponding behaviour. Patients documented daily if they had sunbathed, exposed the shoulders or upper body, used solarium, sunscreen and if they had experienced sunburn. Patients also documented work days, days off and holidays.

6 Results and Discussion

6.1 PDT efficacy

PDT efficacy in terms of AK clearance was investigated in Study I-III and the response rates summarized in Table 2.

cPDT with MAL is an effective AK treatment that can be applied for large skin areas. However, PDT is challenged by lower response rates in transplant recipients in general and in particular for hyperkeratotic AK on the dorsal hands compared to AKs located in the face and scalp (Tyrrell et al., 2011;Morton et al., 2015). PDT is currently the most extensively documented treatment modality for AK in OTRs followed by topical imiquimod (IMIQ), yet no direct comparisons were available at the time of Study I initiation. IMIQ is a Toll-like receptor 7-agonist that locally stimulates the innate and acquired cellular immune response against dysplastic and virus infected cells. Due to its immunostimulatory effects, concern has been raised whether IMIQ could initiate a systemic immune response that may impact the transplanted graft function (Santos-Juanes et al., 2011). The American (FDA) and European (EMA) medicines administrations therefore advise treatment of small skin areas up to 25 cm², although IMIQ is reported safe in doses up to 500 mg total (Ulrich et al., 2007). In contrast, PDT is established as safe for OTRs with no potential graft hazards (Basset-Seguín et al., 2011).

6.1.1 Own investigations

In Study I, we assessed the efficacy according to the licenced usage of cPDT with MAL versus IMIQ for AK on the face/scalp, dorsal forearms or dorsal hands in a split site study design. Patients received at baseline one cPDT and IMIQ treatment session that was repeated at 3 and 2 months respectively, if AK remained. Following 1 and 2 treatment sessions, cPDT achieved higher AK CR rates at 66% (1 treatment) and 78% (2 treatments) compared to 49% and 61% following 1 and 2 IMIQ treatment sessions as shown in Table 2.

Despite being effective for face and scalp lesions, PDT is hampered by significantly lower response rates in thick AK on acral sites, especially in immunosuppressed patients (Tyrrell et al., 2011;Morton et al., 2015;Dragieva et al., 2004a). At initiation of Study II- III, combination of AFL and cPDT had in a few clinical studies shown to significantly enhance AK clearance but also increase LSR compared with cPDT (Togsverd-Bo et al., 2012b;Ko et al., 2013). In Study II-III we aimed to investigate the potential of AFL before PDT to enhance clearance of predominantly thin- moderate AK (Study II) and of predominantly hyperkeratotic, thick acral AK (Study III).

To achieve an augmented PDT response with minimal patient discomfort, Study II explored the combination of AFL pretreatment and dPDT compared with dPDT and cPDT. At 3 months follow up, AFL-dPDT resulted in higher CR rates at 74% compared to CR after dPDT at 46% that were similar

Median Total AK complete response rates						
	IMIQ	cPDT	dPDT	AFXL dPDT	AFXL cPDT	AFXL
Study I						
<i>Face/scalp</i>						
<i>Arms/hands</i>						
1 tx	49% *	66%				
2 tx	61%	78%				
Study II						
<i>All body sites</i>		50%	46%	74%		5%
1 tx						
Study III						
<i>Dorsal hands</i>					73%	31%
1 tx						

Table 2: *Grade I-III AK complete response rate evaluated 3 months after treatment, except following 1 IMIQ session (*) that was evaluated after 1 month.*

to cPDT CR at 50%. AFL alone with these mild settings resulted in 5% CR of AK. Compared with dPDT, AFL pretreatment provided an additive effect of 28% points in AK clearance (grade I-III). We observed a lower CR rate after cPDT in Study II than Study I, which may be explained by a large proportion of non-facial AK in Study II (69% of treatment sites) compared to Study I (34% of treatment sites).

The potential of a more intense AFL treatment alone or in combination with cPDT for thick, keratotic lesions on the dorsal hands was investigated in Study III. Here, we included two AFL passes in terms of lesion-directed treatment and applied significantly higher pulse energies and densities compared to Study II. Following a single treatment only, we obtained 73% CR by AFL-cPDT and 31% CR by AFL alone for grade I-III AK after 4 months. These results are significantly higher than previous PDT studies, reporting response rates between 22-40% CR of acral AK (Dragieva et al., 2004a; Piaserico et al., 2007a). In line with Study II, we observed an especially enhanced efficacy for moderately thick and keratotic AK (grade II+III) at 53% CR following AFL-cPDT compared to 7% CR of grade II-III AK following AFL alone.

In Study I, cPDT induced moderate LSRs that were more intense, but shorter lasting compared to IMIQ. In Study II and III, AFL pretreatment prior to PDT increased LSRs. In Study II, low density laser ablation induced well-tolerated skin reactions characterized by a slightly more intense and longer lasting erythema compared to dPDT and cPDT. In Study III, higher laser settings resulted in significantly more intense and longer lasting erythema as well as edema and crusting compared with reactions observed in Study II. Furthermore, patients were offered local anaesthesia to increase

tolerability of study procedures. These findings indicate that both efficacy and LSR correlate with laser settings in AFL-PDT.

6.1.2 Discussion

The therapeutic effect of cPDT for AK in OTRs is documented in a number of controlled studies and one case series (Dragieva et al., 2004b; Dragieva et al., 2004a; Hasson, 2012; Perrett et al., 2007; Piaserico et al., 2007a; Wennberg et al., 2008; Wulf et al., 2006). At 12-16 weeks after one PDT treatment, studies reported 56% and 68% CR rates on dorsal arms and face/scalp, respectively (Wulf et al., 2006; Dragieva et al., 2004a), which are in accordance with our findings. Studies that applied 2 PDT treatments achieved higher CR at 71-77% in different skin areas and 90% CR at face/scalp areas (Wennberg et al., 2008; Piaserico et al., 2007b; Dragieva et al., 2004b; Perrett et al., 2007). IMIQ treatment achieved in two randomized controlled trials a 73% CR of AK by clinical evaluation after 8 weeks and a 50% histologic CR after 8 months (Brown et al., 2005; Ulrich et al., 2007). In both studies, IMIQ was applied 3 times weekly for 16 weeks. In study I, we observed a lower CR rate at 61% but following only 8 weeks treatment and at 3 months follow-up. In line with previous studies and case reports, (Ulrich et al., 2007; Ulrich et al., 2006; Harwood et al., 2005; Gayed, 2002; Das et al., 2016), we observed no adverse reactions or significant laboratory changes related to graft function.

At initiation of Study II and III, AFL resurfacing in combination with PDT had emerged as a novel technique to enhance PpIX fluorescence and AK efficacy compared with conventional PDT. In these studies, overall AK clearance was improved by 20-40% points following AFL-PDT compared with conventional PDT. By adjusting the laser parameters according to skin thickness and target lesions we aimed to achieve a high AK clearance in moderately thick and thick AK (Study III).

In Study II, AFL treatment at superficial ablation depth and low treatment density increased PDT efficacy in thin or moderately thick AK. In addition, dPDT was for the first time demonstrated to be as effective as cPDT in OTRs. AFL-PDT obtained similar CR rates in Study II and III. However, acral localization of thick keratotic lesions and severe field cancerization in Study III patients resulted in an intensified post-treatment response by AFL-PDT in Study III compared with Study II. These results illustrate that AFL treatment prior to PDT can be tailored for specific lesion types and skin localizations to obtain a continuous high efficacy, even for very difficult-to-treat AK. The enhanced AK treatment response by AFL-PDT was reflected in intensified but tolerable LSR that resolved without long-term adverse reactions.

In conclusion, we found that cPDT was more effective for AK clearance compared with IMIQ, when applied according to the licenced use. IMIQ induced no changes in laboratory values indicating any impact of graft function and was equally preferred by patients as cPDT. By adding AFL pretreatment before both cPDT and dPDT we were able to significantly increase AK clearance rates. The improvement was most pronounced in acral, difficult-to-treat keratotic lesions, and despite intensified LSR, skin areas healed with excellent or good cosmetic results.

6.2 PDT for prevention of skin dysplasia

At Study IV and V initiation, PDT was increasingly reported as effective for secondary AK prevention in terms of reducing further AK development in patients with existing AK (Apalla, 2010; Wennberg et al., 2008; Wulf et al., 2006). However, no human studies had assessed PDT for primary prevention of AK i.e., prevention of first onset of AK in patients with clinically normal skin. The prophylactic effect of PDT with ALA and MAL for SCC prevention was first demonstrated in UV irradiated hairless mice (Stender et al., 1997);(Liu et al., 2004; Sharfaei et al., 2002). While these studies performed repeated PDT treatments, we found a prophylactic effect following two PDT treatments with 20% MAL and 2%-20% HAL-PDT on normal skin in UVR exposed mice (Togsverd-Bo et al., 2010). In OTRs, Wulf prevented development of new AK in 62% of PDT-treated skin areas compared to 35% of untreated control areas by a single MAL-PDT session (Wulf et al., 2006). In a multicentre study, Wennberg et al registered less new AK in skin treated with field-directed PDT compared to lesion-targeted cryotherapy (Wennberg et al., 2008). The clinical effects are supported by reduced p53 patch mutations and upregulation of pro-differentiating cytokines following PDT in field-cancerized skin in immunocompetent patients (Bagazgoitia et al., 2011; Szeimies et al., 2012).

6.2.1 Own investigations

In Study IV, we assess the potential of cPDT for primary prevention of skin dysplasia in renal transplant recipients with no present or history of AK and KC. Patients received split-side MAL-PDT on chronically sun-exposed skin areas every 6 months for 5 years, the contralateral side serving as untreated control. At 6 years inclusion of 25 patients, patients developed significantly more AK in untreated skin compared with the PDT treated side, as shown in Table 4. In total, we observed 76 new AK in untreated skin compared with 21 AK following prophylactic PDT. Correspondingly, the time to first AK was longer at 42 months following PDT-treatment compared to 30 months on the control side. Hence, the probability of 50% of patients having AK on the control area was 42 months compared to 75% on the PDT treated side as shown in Figure 6.

Most patients experienced mild erythema and edema after PDT treatment, however moderate erythema and scaling persisted in some patients following the first 2-3 treatments. To improve patient tolerability, prophylactic low-dose PDT treatments without inflammatory skin reactions would be desirable. Ideally, patients could apply frequent dPDT at low concentration to continuously clear sub-clinical skin photodamage and AK prevention. In Study V we investigated repeated low-concentration HAL-PDT with artificial daylight for SCC prevention in hairless mice irradiated with low and/or intermediate UVR-doses. In mice receiving low and intermediate UVR doses, we observed a 7 day-delay of SCC development following 0.1% HAL-PDT 3 times weekly, whereas mice irradiated with intermittent UVR-dose only did not benefit from PDT.

	PDT treated skin	Untreated control	p
New AK, n	21	76	< 0.01
Areas with AK	10	14	
- tx area with first AK onset	0	14	< 0.001
Median time to AK, months	42	30	0.038
Keratinocyte cancer			
-BCC	0	1	
-SCC	0	0	

Table 3: Number of new AKs and time to AK development by cPDT for primary prevention of skin dysplasia compared with untreated control skin

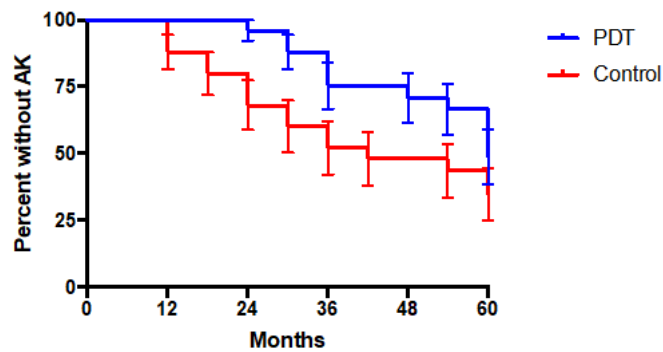


Figure 6: Kaplan-Meier plot of the probability of developing AK in patients treated split-side with PDT vs. no treatment on the face, dorsal forearm and hand. At 42 months, 50% of patients had developed AK.

6.2.2 Discussion

In Study IV, PDT prevented first onset of AK whereas no patients developed any SCCs. Although we were unable to assess the prophylactic effect of SCC in the current study, AK are a major risk factor for SCC development in OTRs (Wallingford et al., 2015; Bouwes Bavinck et al., 2007). Two studies have assessed PDT for SCC prevention in transplant recipients. In an RCT, OTRs with field cancerization received 2 ALA-PDT sessions at baseline, but had similar SCC incidence in PDT- and untreated skin areas at 2 years follow-up (de Graaf et al., 2006). In an uncontrolled before-and-after study, Willey et al performed multiple PDT treatments to reduce the rate of SCC in OTRs with a history of frequent SCCs (Willey et al., 2010). These clinical studies as well as our results suggest a potential of PDT to prevent or delay AK and possibly SCC, but also indicate the need for repeated treatments to obtain a longer-lasting antineoplastic effect.

In Study V, we found a limited effect of repeated low-intensity HAL-PDT with minimal skin inflammation to delay SCCs in mice. The studies of HAL-PDT for therapeutic purposes is low, although PDT with 0.2% HAL was recently shown equally effective as 20% MAL-PDT for thin AKs (Neittaanmaki-Perttu et al., 2016). Hence, repeated low-concentration PDT at higher HAL concentration or at increased treatment intervals may have a long-term preventative effect on AK in high-risk patients.

In conclusion, we found a primary prophylactic effect of repeated cPDT with MAL in sun exposed, but clinically normal skin to delay the onset of first actinic skin dysplasia in renal transplant recipients. Repeated low-concentration HAL-PDT with artificial daylight showed a small reduction of UVR-induced SCCs in mice. A prophylactic benefit of PDT was observed in some OTRs whereas other patients did not develop any AK during the study period. This illustrates the need of non-invasive methods that may quantify patients' skin photodamage and differentiate patients that could benefit from prophylactic treatments.

6.3 Non-invasive measurements of skin photodamage and UVR exposure

It is desirable to develop non-invasive, objective measures of skin photodamage that ideally can estimate patients' individual risk of KC development. Non-invasive methods to distinct photodamage from chronological ageing are furthermore attractive. Previous studies indicate that changes in skin autofluorescence from collagen fibres, tryptophan and to a lesser extent, elastin fibres can be used as a marker of skin photodamage (Na et al., 2001a; Sandby-Moller et al., 2004; Kollias et al., 1998). Furthermore, individually measured UVR exposure showed positive associations between previous and current UVR exposure, and changes in skin pigmentation (Lock-Andersen et al., 1998) (Thieden et al., 2006) and solar lentigines density (Thieden et al., 2005b; Bastiaens et al., 2004).

6.3.1 Own investigation

In Study VI and VII, we investigated objective photodamage in terms of skin autofluorescence at 370 nm and 430 nm excitation (F370 and F430, respective), pigmentation and density of solar lentigines in OTR and immunocompetent patients with KC. Associations between objective photodamage parameters and prospectively measured individual UVR exposure were also investigated. In Study VI, F370 skin autofluorescence values on the shoulder and arm were higher in KC patients than in patients without KC, see Table 4. Furthermore, F370 shoulder fluorescence was in conjunction with patient age associated with skin cancer at OR 10.5; and correlated positively with individually measured UVR exposure doses. In the majority of OTR with KC, measured fluorescence values lay above a cut off at $\ln F370 = 7.2$. From the personal dosimeter data, we observed higher total UVR exposure dose in OTRs with skin cancer than OTRs without skin cancer. The higher UVR exposure dose was reflected in a larger increase in F-PPF on the lateral arm during the summer period.

In Study VII, objective photodamage was compared between OTRs with KC and age- and gender matched immunocompetent patients with KC (non-OTRs). Consistent with Study VI, OTRs expressed higher F370 fluorescence on the shoulder and adjacent to KC sites compared with non-OTRs. In both Study VI and VII, the density of solar lentigines was higher in OTRs with KC than non-OTRs and OTRs without KC. These findings may reflect an accelerated progression of photodamage in OTRs with KC versus non-OTRs, but also reflects a lifestyle with more UVR exposure than in OTRs with KC than without KC.

6.3.2 Discussion

Objectively quantified skin photodamage and quantified UVR dosimetry in OTRs are to a limited extent reported in the literature. In previous studies, qualitative assessments of photodamage including solar lentigines, wrinkles and AK were positively associated with patient reported previous sunburns and sun exposure (Terhorst et al., 2009; Surber et al., 2012). These studies may however, be hampered with recall bias. Collagen-related autofluorescence has previously been investigated in normal and

	OTRs - skin cancer	OTR + skin cancer	Non-OTR + skin cancer
Patient age, years <i>Study VI</i> <i>Study VII</i>	49 (36-67)	57 (37-67) 60 (45-77)	62 (47-78)
Fitzpatrick ST I/II/III <i>Study VI</i> <i>Study VII</i>	1/8/6 -	1/4/8 3/8/3	- 2/9/2
Time since transplant, years <i>Study VI</i> <i>Study VII</i>	5 (1-17) -	12 (4-24) 13 (6-28)	-
F370 shoulder <i>Study VI</i> <i>Study VII</i>	1381 -	2017 1898	- 1525
F370 lateral arm <i>Study VI</i> <i>Study VII</i>	1701 -	2096 1458	- 1480
F370 Skin cancer site <i>Study VII</i>	-	2208	1685
C-PPF <i>Study VI</i> <i>Study VII</i>	4.0	4.0 2.9	- 2.8
F-PPF shoulder <i>Study VI</i> <i>Study VII</i>	7.6	8.8 7.6	- 6.5
Solar lentigines shoulder <i>Study VI</i> <i>Study VII</i>	2.0 -	3.0 3.0	- 2.5

Table 4: *Skin pigmentation (PPF), autofluorescence at 370 nm excitation (F370) and solar lentigines density in studies VI +VII.*

UVR-exposed human skin and in hairless mice. Sandby-Møller et al assessed collagen-autofluorescence at 330 nm and 370 nm excitation in patients equipped with similar personal UVR dosimeters as used in study VII (Sandby-Møller et al., 2004). The authors found enhanced autofluorescence with increasing age, but no association with UVR exposure. In murine skin, decreased autofluorescence at 340 nm and 360 nm excitation is reported in UVR irradiated skin vs. un-irradiated skin (Kollias et al., 1998), whereas Na et al showed increased 370 nm excitation-induced autofluorescence at the forehead vs. sun-protected buttock skin (Na et al., 2000). Based on these results, autofluorescence from collagen-crosslinks may be useful to describe photodamage but require further evaluations.

In conclusion, we found that skin autofluorescence at 370 nm excitation measured on the shoulder was associated with UVR exposure dose, solar lentigines, age and skin cancer in OTRs. OTRs with KC had higher 370nm fluorescence values on the shoulders than immunocompetent controls indicating more severe skin photodamage. Our findings suggest a potential of photodamage estimated by autofluorescence at 370 nm, pigmentation and density of solar lentigines for objective measurement for skin photodamage and risk of KC development in OTRs.

7 Conclusions

From the studies based on this thesis, the main conclusions were:

- Conventional PDT was more effective for AK clearance, but resulted in more severe skin reactions than IMIQ when applied according to licenced dosage. Used in small skin areas, IMIQ induced no significant changes in laboratory values indicating affected graft function.
- Daylight and conventional PDT were equally effective to achieve AK clearance 3 months after treatment and produced similar skin reactions.
- Pretreatment with AFL before PDT significantly increased AK clearance compared to both conventional PDT and daylight PDT.
- By tailoring AFL parameters to the level of keratoses, patients achieved high AK complete response of thin AK as well as hyperkeratotic AK on the dorsal hands from a single AFL-PDT treatment. The intensity of local skin reactions increased correspondingly with higher laser setting after both AFL-PDT and AFL alone.
- Conventional MAL-PDT was effective for primary prevention of first onset of AKs in renal transplant recipients with clinically normal skin. Repeated PDT sessions twice yearly for 5 years significantly reduced the number of new AK and delayed the time to first onset of AK compared with no treatment.
- In murine skin, repeated low-concentration PDT with 0.02-0.1% HAL and artificial daylight marginally prevented SCC development. Low concentrations of HAL-PDT induced minimally inflammatory skin reactions that enabled PDT treatments 1 -3 times per week.
- Skin photodamage could be objectively measured as skin pigmentation, skin autofluorescence at 370 nm and solar lentigines density on the shoulder. Our findings suggest the shoulder and upper arm are useful sites for objective skin photodamage measurements.
- Skin autofluorescence at 370 nm on the shoulder correlated with skin cancer, UVR exposure dose and years since transplantation. In 89% of patients with skin cancer, lnF370 nm autofluorescence was >7.2 . Adjacent to skin cancer sites, OTRs expressed enhanced 370 nm autofluorescence values compared with immunocompetent patients.
- Solar lentigines density correlated with patient age, number of skin cancers and F370 nm on the shoulders. Also, skin pigmentation on the arm correlated with UVR exposure dose and was associated with solar lentigines density.

- Our findings suggest a potential of photodamage estimated by autofluorescence at 370 nm, pigmentation and density of solar lentigines as an objective measurement for risk of KC development in OTRs.

8 Perspectives

The results obtained by studies in this thesis build upon Danish and Swedish solid OTRs with different transplanted organ and different years since transplantation and receiving immunosuppressive treatment. We included OTRs with no skin dysplasia as well as patients transplanted over 42 years ago with multiple dysplastic lesions. These patients obviously have different needs for dermatologic treatment and surveillance.

We found combination of AFL and PDT with both conventional LED light and daylight significantly increased AK clearance compared to cPDT and dPDT. By increasing laser energy to level of hyperkeratosis, we sustained a high efficacy for thick AK. These findings underscore the potential of AFL-PDT to be offered as a routine treatment for patients with difficult-to-treat hyperkeratotic AK. AFL-PDT with LED light was associated with severe inflammatory reactions and adjusting laser settings to achieve enhanced efficacy with tolerable local skin reactions needs to be established. MAZ dimensions following AFL exposure has primarily been assessed in normal skin or pig skin, which may not be transferable to keratotic AK. Investigation of the relation between histologic characterization of MAZ dimensions, AFL settings and biologic response in hyperkeratotic AK should therefore be investigated.

Over a 5-year period, primary prevention with cPDT with MAL delayed AK onset in renal transplant recipients with normal skin and no previous skin dysplasia. Similar preventative results may be achieved by dPDT and should be investigated including all OTRs and not only renal transplant recipients. Prophylactic dPDT of sun-exposed skin areas could be achieved at 6-month intervals, as dPDT is possible 7 months per year in countries of northern latitude such as Denmark. Hence, prophylactic dPDT treatments would be easy for patients and dermatologic clinics to perform and could be feasible in an everyday setting.

Although we found artificial dPDT with low-concentration HAL to only marginally delay of SCC in hairless mice, a greater prophylactic effect may be achieved by increasing photosensitizer concentration and the effective light dose. While higher photosensitizer concentration probably would enhance inflammatory reactions after PDT treatment, intervals could be reduced. Murine studies to explore the balance between increased PDT effect of AK/SCC prevention with inflammatory reactions and treatment intervals are therefore warranted.

Approximately one third of renal transplant recipients included for prophylactic PDT did not develop any AK during the study period. This imply that PDT for primary prophylaxis is beneficial in some patients, possibly with subclinical skin dysplasia.

To identify OTRs at higher risk of KC development, objective and non-invasive measurements of skin photodamage could be valuable in combination with other individual risk factors such as history of UVR exposure and immunosuppressive medication. Ideally, objectively measured photodamage would summarize the biologic effects of UVR exposure with individual photosensitivity in each patient.

Studies to further assess skin autofluorescence, pigmentation and lentigines in a large subset of both immunosuppressed and immunocompetent patients are needed to establish a modified reference area. A prospective cohort design could describe the time course of photodamage development after organ transplantation and their correlation with AK and KC development.

In the future, objectively measured and established risk parameters may be linked with cutaneous mRNA expression of p53 to identify patients with higher level of subclinical actinic field damage. A marker of the cutaneous immunosuppression is also highly desirable since both iatrogen and UVR-induced immunosuppression are important components in skin photocarcinogenesis.

The scope of this thesis was to explore the potential of personalized AK treatment and prevention modalities for OTRs with different needs of AK prevention and treatment. For further perspectives, the potential of objective photodamage to obtain an individual assessment of skin cancer risk would assist clinicians in risk stratification of patients.

9 Dansk resume

Thesis title: Keratinocyte dysplasia in organ transplant recipients: Treatment and prevention with photodynamic therapy and non-invasively measured skin photodamage

Organtransplanterede patienter (OTP) i immunsupprimerende behandling har i forhold til baggrundsbeholdningen en markant øget risiko for at udvikle aktiniske keratoser (AK) og keratinocyt derivet hudcancer (KC), særligt planocellulært carcinom (SCC). Risikoen for KC stiger med øget tid efter organtransplantation og den kumulerede risiko for KC er op til 75% af patienterne 20-30 år efter organtransplantation. SCC har ydermere et mere aggressivt vækstmønster med større risiko for metastasering og heraf følgende mortalitet hos OTP end hos immunkompetente patienter.

AK er forstadier til SCC og en kendt risikofaktor for udvikling af SCC, særligt ved udbredning i større område med kronisk solskade, betegnet field cancerization. Fotodynamisk terapi (PDT) med methyl aminolevulinat (MAL) er en attraktiv behandling af AK og field cancerization og er særlig velegnet til behandling af større hudområder. PDT har endvidere vist at kunne forebygge nye AK i de behandlede hudområder. Desværre er effekten af PDT lav for tykke AK i akrale hudområder og er vist at være nedsat ved behandling af AK hos OTP i forhold til immunkompetente patienter.

Målet med denne afhandling var at øge PDT's effekt for AK hos OTP, at undersøge effekten af PDT til primær forebyggelse af AK og KC hos nyretransplanterede og at undersøge relationen mellem non-invasiv måling af solskade i huden hos OTP med og uden hudcancer. Dette overordnede mål blev undersøgt i tre afsnit.

I det første afsnit undersøgte vi effekten af konventionel PDT (cPDT) versus imiquimod til fjernelse af AK. Herefter søgte vi at øge effekten af PDT til tynde og keratotiske AK ved forbehandling af huden med ablativ fraktioneret laserbehandling (AFL) før cPDT og dagslys PDT (dPDT). I det første studie sammenlignede vi effekten af 1 eller 2 behandlingsserier med PDT og imiquimod af ansigt/skalp, underarm og håndryg i henhold til den indregistrerede dosering. cPDT opnåede tre måneder efter sidste behandling en højere effekt rate (clearance) af AK i forhold til imiquimod. cPDT resulterede i kraftigere, men kortere varende lokale hudreaktioner efter behandlingen end imiquimod. Patienterne foretrak begge behandlinger i lige høj grad. For at øge penetrationen af MAL og dermed effekten af PDT, kombinerede vi dPDT med overfladisk AFL-behandling med lav densitet til behandling af overvejende tynde AK. Tre måneder efter en enkelt behandling opnåede AFL-dPDT en højere effektrate af AK på 74% sammenlignet med cPDT (50%) og dPDT (46%) samt AFL alene (5%). Til behandling af tykke, keratotiske AK på håndryggene, blev cPDT kombineret med AFL behandling givet ved højere energi og med tættere densitet. Ved disse indstillinger opnåede AFL-cPDT en effektrate på 73%, mens AFL alene fjernede 31% af AKerne. Forbehandling af huden med AFL før både cPDT og dPDT forstærkede hudreaktionerne efter PDT i mild grad ved overfladisk AFL-behandling og dPDT, samt i moderat-svær grad ved kraftigere laser settings og cPDT.

I det andet afsnit undersøgte vi om forebyggende cPDT på klinisk normal hud er effektiv til primær

forebyggelse af huddysplasi hos nyretransplanterede patienter. Patienterne blev behandlet med cPDT i den ene halvdel af ansigtet, underarm og håndryg 2 gange årligt i 5 år, mens den modsatte side var en ubehandlet kontrol. Efter 6 år havde 25 patienter udviklet signifikant færre AK på den PDT-behandlede side i forhold til den ubehandlede side (n=76). Median tiden indtil patienterne udviklede AK var 42 måneder på PDT-behandlede områder og 30 måneder på ubehandlede områder. Ingen patienter udviklede SCC. Selvom hudreaktionerne efter PDT overordnet var milde, ønskede vi at forbedre tolerabiliteten ved forebyggende PDT. Derfor undersøgte vi om PDT med kunstigt dagslys i lav-inflammations doser kunne forebygge SCC hos UV-bestrålede hårløse mus. Vi fandt at mus belyst med en lav + intermediær UV-dosis havde en lille, men dog signifikant udsættelse af SCC ved 0.1% hexyl aminolevulinat givet 3 gange om ugen. Imidlertid fandt vi ingen effekt ved PDT med lavere koncentrationer eller hos mus belyst udelukkende med intermediær UV-dosis.

I det tredje afsnit undersøgte vi non-invasive målinger af solskade i huden vurderet ved autofluorescens, pigmentering og tæthed af solare lentiginer hos OTP med og uden hudcancer. Solskade målingerne blev sammenholdt med prospektive individuelle UV-eksponeringsdoser ud fra personlige dosimetri målt over en sommer. Vi fandt at OTP med hudcancer havde en øget UV eksponeringsdosis, mere pigmentering og højere autofluorescens ved 370 nm. 370 nm autofluorescens, som afspejler kollagen nedbrydningsprodukter, målt på skulderen var associeret med UV eksponeringsdosis, tæthed af solare lentiginer, alder og hudcancer. Ydermere fandt vi at 370 nm autofluorescens på skulderen og ved hudcancer var øget hos OTP sammenlignet med matchede immunkompetente hudcancer patienter.

Den overordnede konklusion på denne afhandling er, at PDT er en effektiv behandling af AK hos OTP og at behandlingseffekten kan øges i kombination med AFL-behandling. Ved at justere AFL settings ud fra tykkelsen af AK, kan der opnås en høj effekt i behandling af både tynde AK og tykke AK. Primær forebyggelse med gentagne cPDT behandlinger udsatte tiden til AK hos nyretransplanterede patienter, mens lav-dosis PDT hos UV-belyste hårløse mus resulterede i en mindre forsinkelse i udvikling af SCC. Endelig fandt vi at non-invasive målinger af solskade var associeret med hudcancer og UV eksponeringsdosis og kan muligvis bruges til at identificere OTP, der er i særlig risiko for at udvikle hudcancer.

10 Reference List

1. Agostinis P, Berg K, Cengel KA, Foster TH, Girotti AW, Gollnick SO, Hahn SM, Hamblin MR, Juzeniene A, Kessel D, Korbelik M, Moan J, Mroz P, Nowis D, Piette J, Wilson BC, Golab J: Photodynamic therapy of cancer: an update. *CA Cancer J Clin* 61:250-281 (2011).
2. Amano S: Characterization and mechanisms of photoageing-related changes in skin. Damages of basement membrane and dermal structures. *Exp Dermatol* 25 Suppl 3:14-19 (2016).
3. Anderson RR: Laser-Tissue Interactions, Almond G (ed): Cutaneous Laser Surgery. The art and science of selective photothermolysis 2 ed., pp 1-18 (Mosby, St.Louis 2007).
4. Anderson RR, Parrish JA: The optics of human skin. *J Invest Dermatol* 77:13-19 (1981).
5. Anderson RR, Parrish JA: Selective photothermolysis: precise microsurgery by selective absorption of pulsed radiation. *Science* 220:524-527 (1983).
6. Apalla Z: Skin cancer: preventive photodynamic therapy in patients with face and scalp cancerization. A randomized placebo-controlled study. (2010).
7. Arron ST, Ruby JG, Dybbro E, Ganem D, Derisi JL: Transcriptome sequencing demonstrates that human papillomavirus is not active in cutaneous squamous cell carcinoma. *J Invest Dermatol* 131:1745-1753 (2011).
8. Attard NR, Karran P: UVA photosensitization of thiopurines and skin cancer in organ transplant recipients. *Photochem Photobiol Sci* 11:62-68 (2012).
9. Bagazgoitia L, Cuevas SJ, Juarranz A, Jaen P: Photodynamic therapy reduces the histological features of actinic damage and the expression of early oncogenic markers. *Br J Dermatol* 165:144-151 (2011).
10. Basset-Seguín N, Baumann CK, Gerritsen MJ, Gonzalez H, Haedersdal M, Hofbauer GF, Aguado L, Kerob D, Lear JT, Piaserico S, Ulrich C: Photodynamic therapy for actinic keratosis in organ transplant patients. *J Eur Acad Dermatol Venereol* (2011).
11. Bastiaens M, Hoefnagel J, Westendorp R, Vermeer BJ, Bouwes Bavinck JN: Solar lentigines are strongly related to sun exposure in contrast to ephelides. *Pigment Cell Res* 17:225-229 (2004).
12. Bay C, Lerche CM, Ferrick B, Philipsen PA, Togsverd-Bo K, Haedersdal M: Comparison of Physical Pretreatment Regimens to Enhance Protoporphyrin IX Uptake in Photodynamic Therapy: A Randomized Clinical Trial. *JAMA Dermatol* 153:270-278 (2017).
13. Berman B, Cockerell CJ: Pathobiology of actinic keratosis: ultraviolet-dependent keratinocyte proliferation. *J Am Acad Dermatol* 68:S10-S19 (2013).

14. Blomberg M, He SY, Harwood C, Arron ST, Demehri S, Green A, Asgari MM: Research gaps in the management and prevention of cutaneous squamous cell carcinoma in organ transplant recipients. *Br J Dermatol* (2017).
15. Bouwes Bavinck JN, Euvrard S, Naldi L, Nindl I, Proby CM, Neale R, Abeni D, Tessari GP, Feltkamp MC, Claudy A, Stockfleth E, Harwood CA: Keratotic skin lesions and other risk factors are associated with skin cancer in organ-transplant recipients: a case-control study in The Netherlands, United Kingdom, Germany, France, and Italy. *J Invest Dermatol* 127:1647-1656 (2007).
16. Braathen LR, Morton CA, Basset-Seguin N, Bissonnette R, Gerritsen MJ, Gilaberte Y, Calzavara-Pinton P, Sidoroff A, Wulf HC, Szeimies RM: Photodynamic therapy for skin field cancerization: an international consensus. *International Society for Photodynamic Therapy in Dermatology. J Eur Acad Dermatol Venereol* 26:1063-1066 (2012).
17. Braathen LR, Szeimies RM, Basset-Seguin N, Bissonnette R, Foley P, Pariser D, Roelandts R, Wennberg AM, Morton CA: Guidelines on the use of photodynamic therapy for nonmelanoma skin cancer: an international consensus. *International Society for Photodynamic Therapy in Dermatology, 2005. J Am Acad Dermatol* 56:125-143 (2007).
18. Brancalion L, Moseley H: Laser and non-laser light sources for photodynamic therapy. *Lasers Med Sci* 17:173-186 (2002).
19. Brown VL, Atkins CL, Ghali L, Cerio R, Harwood CA, Proby CM: Safety and efficacy of 5% imiquimod cream for the treatment of skin dysplasia in high-risk renal transplant recipients: randomized, double-blind, placebo-controlled trial. *Arch Dermatol* 141:985-993 (2005).
20. Byrne SN: Mast cell migration from the skin to the draining lymph nodes upon ultraviolet irradiation represents a key step in the induction of immune suppression. (2008).
21. Calne RY: A Brief History of Clinical Organ Transplantation, Kirk AD, Knechtle SJ, Larsen CP, Madsen JC, Pearson TC, Webber SA (eds): *Textbook of Organ Transplantation* 1 ed., pp 5-12 (John Wiley & Sons, 2014).
22. Choi SH: Efficacy of ablative fractional laser-assisted photodynamic therapy with short-incubation time for the treatment of facial and scalp actinic keratosis: 12-month follow-up results of a randomized, prospective, comparative trial. (2015).
23. Choi SH, Kim KH, Song KH: Er:YAG ablative fractional laser-primed photodynamic therapy with methyl aminolevulinate as an alternative treatment option for patients with thin nodular basal cell carcinoma: 12-month follow-up results of a randomized, prospective, comparative trial. *J Eur Acad Dermatol Venereol* 30:783-788 (2016).

24. Christensen E, Warloe T, Kroon S, Funk J, Helsing P, Soler AM, Stang HJ, Vatne O, Mork C: Guidelines for practical use of MAL-PDT in non-melanoma skin cancer. *J Eur Acad Dermatol Venereol* 24:505-512 (2010).
25. Coghill AE, Johnson LG, Berg D, Resler AJ, Leca N, Madeleine MM: Immunosuppressive Medications and Squamous Cell Skin Carcinoma: Nested Case-Control Study Within the Skin Cancer after Organ Transplant (SCOT) Cohort. *Am J Transplant* 16:565-573 (2016).
26. Collett D, Mumford L, Banner NR, Neuberger J, Watson C: Comparison of the incidence of malignancy in recipients of different types of organ: a UK Registry audit. *Am J Transplant* 10:1889-1896 (2010).
27. Damian DL: An action spectrum for ultraviolet radiation-induced immunosuppression in humans. (2011).
28. Dang C, Koehler A, Forschner T, Sehr P, Michael K, Pawlita M, Stockfleth E, Nindl I: E6/E7 expression of human papillomavirus types in cutaneous squamous cell dysplasia and carcinoma in immunosuppressed organ transplant recipients. *Br J Dermatol* 155:129-136 (2006).
29. Das G, Tan B, Nicholls K: Safety and efficacy of a novel short occlusive regimen of imiquimod for selected non-melanotic skin lesions in renal transplant patients. *Intern Med J* 46:352-355 (2016).
30. de Graaf YG, Kennedy C, Wolterbeek R, Collen AF, Willemze R, Bouwes Bavinck JN: Photodynamic therapy does not prevent cutaneous squamous-cell carcinoma in organ-transplant recipients: results of a randomized-controlled trial. *J Invest Dermatol* 126:569-574 (2006).
31. de Gruijl FR: Photobiology of photocarcinogenesis. *Photochem Photobiol* 63:372-375 (1996).
32. de Gruijl FR: Photocarcinogenesis: UVA vs UVB. *Methods Enzymol* 319:359-366 (2000).
33. de Gruijl FR, Rebel H: Early events in UV carcinogenesis--DNA damage, target cells and mutant p53 foci. *Photochem Photobiol* 84:382-387 (2008).
34. de Gruijl FR, Van Kranen HJ, Mullenders LH: UV-induced DNA damage, repair, mutations and oncogenic pathways in skin cancer. *J Photochem Photobiol B* 63:19-27 (2001).
35. de Gruijl FR, Voskamp P: Photocarcinogenesis--DNA damage and gene mutations. *Cancer Treat Res* 146:101-108 (2009).
36. Dessinioti C, Tzannis K, Sypsa V, Nikolaou V, Kypreou K, Antoniou C, Katsambas A, Stratigos AJ: Epidemiologic risk factors of basal cell carcinoma development and age at onset in a Southern European population from Greece. *Exp Dermatol* 20:622-626 (2011).

37. Dragieva G, Hafner J, Dummer R, Schmid-Grendelmeier P, Roos M, Prinz BM, Burg G, Binswanger U, Kempf W: Topical photodynamic therapy in the treatment of actinic keratoses and Bowen's disease in transplant recipients. *Transplantation* 77:115-121 (2004a).
38. Dragieva G, Prinz BM, Hafner J, Dummer R, Burg G, Binswanger U, Kempf W: A randomized controlled clinical trial of topical photodynamic therapy with methyl aminolaevulinate in the treatment of actinic keratoses in transplant recipients. *Br J Dermatol* 151:196-200 (2004b).
39. Dziunycz PJ, Lefort K, Wu X, Freiberger SN, Neu J, Djerbi N, Iotzowa-Weiss G, French LE, Dotto GP, Hofbauer GFL: The oncogene ATF3 is potentiated by cyclosporine A and ultraviolet light A. *J Invest Dermatol* 134:1998-2004 (2014).
40. Erlendsson AM, Anderson RR, Manstein D, Waibel JS: Developing technology: ablative fractional lasers enhance topical drug delivery. *Dermatol Surg* 40 Suppl 12:S142-S146 (2014).
41. Euvrard S, Chardonnet Y, Pouteil-Noble C, Kanitakis J, Chignol MC, Thivolet J, Touraine JL: Association of skin malignancies with various and multiple carcinogenic and noncarcinogenic human papillomaviruses in renal transplant recipients. *Cancer* 72:2198-2206 (1993).
42. Euvrard S, Kanitakis J, Pouteil-Noble C, Claudy A, Touraine JL: Skin cancers in organ transplant recipients. *Ann Transplant* 2:28-32 (1997).
43. Euvrard S, Morelon E, Rostaing L, Goffin E, Brocard A, Tromme I, Broeders N, Del M, V, Chatelet V, Dompmartin A, Kessler M, Serra AL, Hofbauer GF, Pouteil-Noble C, Campistol JM, Kanitakis J, Roux AS, Decullier E, Dantal J: Sirolimus and secondary skin-cancer prevention in kidney transplantation. *N Engl J Med* 367:329-339 (2012).
44. Figueras N, I, Cerio R, Dirschka T, Dreno B, Lear JT, Pellacani G, Peris K, Ruiz de CA: Defining the actinic keratosis field: a literature review and discussion. *J Eur Acad Dermatol Venereol* (2017).
45. Flynn GL: Cutaneous and Transdermal Delivery: Processes and Systems of Delivery, Banker GS, Rhodes CT (eds): *Modern Pharmaceutics* 3. ed., pp 239-298 (Marcel Dekker, New York 1997).
46. Forster B, Klein A, Szeimies RM, Maisch T: Penetration enhancement of two topical 5-aminolaevulinic acid formulations for photodynamic therapy by erbium:YAG laser ablation of the stratum corneum: continuous versus fractional ablation. *Exp Dermatol* 19:806-812 (2010).
47. Fotinos N, Campo MA, Popowycz F, Gurny R, Lange N: 5-Aminolevulinic acid derivatives in photomedicine: Characteristics, application and perspectives. *Photochem Photobiol* 82:994-1015 (2006).

48. Fritsch C, Homey B, Stahl W, Lehmann P, Ruzicka T, Sies H: Preferential relative porphyrin enrichment in solar keratoses upon topical application of delta-aminolevulinic acid methylester. *Photochem Photobiol* 68:218-221 (1998).
49. Gamble RG, Asdigian NL, Aalborg J, Gonzalez V, Box NF, Huff LS, Baron AE, Morelli JG, Mokrohisky ST, Crane LA, Dellavalle RP: Sun damage in ultraviolet photographs correlates with phenotypic melanoma risk factors in 12-year-old children. *J Am Acad Dermatol* 67:587-597 (2012).
50. Gao Y, Twigg AR, Hirose R, Roll GR, Nowacki AS, Maytin EV, Vidimos AT, Rajalingam R, Arron ST: Association of HLA Antigen Mismatch With Risk of Developing Skin Cancer After Solid-Organ Transplant. *JAMA Dermatol* (2019).
51. Garg AD, Nowis D, Golab J, Agostinis P: Photodynamic therapy: illuminating the road from cell death towards anti-tumour immunity. *Apoptosis* 15:1050-1071 (2010).
52. Garrett GL, Blanc PD, Boscardin J, Lloyd AA, Ahmed RL, Anthony T, Bibee K, Breithaupt A, Cannon J, Chen A, Cheng JY, Chiesa-Fuxench Z, Colegio OR, Curiel-Lewandrowski C, Del Guzzo CA, Disse M, Dowd M, Eilers R, Jr., Ortiz AE, Morris C, Golden SK, Graves MS, Griffin JR, Hopkins RS, Huang CC, Bae GH, Jambusaria A, Jennings TA, Jiang SI, Karia PS, Khetarpal S, Kim C, Klintmalm G, Konicke K, Koymfman SA, Lam C, Lee P, Leitenberger JJ, Loh T, Lowenstein S, Madankumar R, Moreau JF, Nijhawan RI, Ochoa S, Olasz EB, Otchere E, Otley C, Oulton J, Patel PH, Patel VA, Prabhu AV, Pugliano-Mauro M, Schmults CD, Schram S, Shih AF, Shin T, Soon S, Soriano T, Srivastava D, Stein JA, Sternhell-Blackwell K, Taylor S, Vidimos A, Wu P, Zajdel N, Zelac D, Arron ST: Incidence of and Risk Factors for Skin Cancer in Organ Transplant Recipients in the United States. *JAMA Dermatol* 153:296-303 (2017).
53. Garrett GL, Lowenstein SE, Singer JP, He SY, Arron ST: Trends of skin cancer mortality after transplantation in the United States: 1987 to 2013. *J Am Acad Dermatol* 75:106-112 (2016).
54. Gayed SL: Topical imiquimod cream 5% for resistant perianal warts in a renal transplant patient. *Int J STD AIDS* 13:501-503 (2002).
55. Gerritsen MJ, Smits T, Kleinpenning MM, van de Kerkhof PC, van Erp PE: Pretreatment to enhance protoporphyrin IX accumulation in photodynamic therapy. *Dermatology* 218:193-202 (2009).
56. Gilchrest BA, Fitzpatrick TB, Anderson RR, Parrish JA: Localization of malanin pigmentation in the skin with Wood's lamp. *Br J Dermatol* 96:245-248 (1977).
57. Gillies R, Zonios G, Anderson RR, Kollias N: Fluorescence excitation spectroscopy provides information about human skin in vivo. *J Invest Dermatol* 115:704-707 (2000).

58. Gogia R, Binstock M, Hirose R, Boscardin WJ, Chren MM, Arron ST: Fitzpatrick skin phototype is an independent predictor of squamous cell carcinoma risk after solid organ transplantation. *J Am Acad Dermatol* 68:585-591 (2013).
59. Gueranger Q, Li F, Peacock M, Larnicol-Fery A, Brem R, Macpherson P, Egly JM, Karran P: Protein oxidation and DNA repair inhibition by 6-thioguanine and UVA radiation. *J Invest Dermatol* 134:1408-1417 (2014a).
60. Gueranger Q, Li F, Peacock M, Larnicol-Fery A, Brem R, Macpherson P, Egly JM, Karran P: Protein oxidation and DNA repair inhibition by 6-thioguanine and UVA radiation. *J Invest Dermatol* 134:1408-1417 (2014b).
61. Haak CS, Christiansen K, Erlendsson AM, Taudorf EH, Thaysen-Petersen D, Wulf HC, Haedersdal M: Ablative fractional laser enhances MAL-induced PpIX accumulation: Impact of laser channel density, incubation time and drug concentration. *J Photochem Photobiol B* 159:42-48 (2016).
62. Haak CS, Farinelli WA, Tam J, Doukas AG, Anderson RR, Haedersdal M: Fractional laser-assisted delivery of methyl aminolevulinate: Impact of laser channel depth and incubation time. *Lasers Surg Med* 44:787-795 (2012).
63. Haak CS, Togsverd-Bo K, Thaysen-Petersen D, Wulf HC, Paasch U, Anderson RR, Haedersdal M: Fractional laser-mediated photodynamic therapy of high-risk basal cell carcinomas - a randomized clinical trial. *Br J Dermatol* (2014).
64. Haedersdal M, Erlendsson AM, Paasch U, Anderson RR: Translational medicine in the field of ablative fractional laser (AFXL)-assisted drug delivery: A critical review from basics to current clinical status. *J Am Acad Dermatol* 74:981-1004 (2016).
65. Haedersdal M, Katsnelson J, Sakamoto FH, Farinelli WA, Doukas AG, Tam J, Anderson RR: Enhanced uptake and photoactivation of topical methyl aminolevulinate after fractional CO₂ laser pretreatment. *Lasers Surg Med* 43:804-813 (2011).
66. Haedersdal M, Sakamoto FH, Farinelli WA, Doukas AG, Tam J, Anderson RR: Fractional CO₂ laser-assisted drug delivery. *Lasers Surg Med* 42:113-122 (2010).
67. Halldin CB, Gillstedt M, Paoli J, Wennberg AM, Gonzalez H: Predictors of pain associated with photodynamic therapy: a retrospective study of 658 treatments. *Acta Derm Venereol* 91:545-551 (2011).
68. Halliday GM, Byrne SN, Damian DL: Ultraviolet A radiation: its role in immunosuppression and carcinogenesis. *Semin Cutan Med Surg* 30:214-221 (2011).

69. Hart PH, Norval M: Ultraviolet radiation-induced immunosuppression and its relevance for skin carcinogenesis. *Photochem Photobiol Sci* 17:1872-1884 (2018).
70. Harwood CA, Perrett CM, Brown VL, Leigh IM, McGregor JM, Proby CM: Imiquimod cream 5% for recalcitrant cutaneous warts in immunosuppressed individuals. *Br J Dermatol* 152:122-129 (2005).
71. Harwood CA, Toland AE, Proby CM, Euvrard S, Hofbauer GFL, Tommasino M, Bouwes Bavinck JN: The pathogenesis of cutaneous squamous cell carcinoma in organ transplant recipients. *Br J Dermatol* 177:1217-1224 (2017).
72. Hasson A: Topical photodynamic therapy with methylaminolevulinate for the treatment of actinic keratosis and reduction of photodamage in organ transplant recipients: a case-series of 16 patients. (2012).
73. Henderson BW, Dougherty TJ: How does photodynamic therapy work? *Photochem Photobiol* 55:145-157 (1992).
74. Hofbauer GF, Anliker M, Arnold A, Binet I, Hunger R, Kempf W, Laffitte E, Lapointe AC, Pascual M, Pelloni F, Serra A: Swiss clinical practice guidelines for skin cancer in organ transplant recipients. *Swiss Med Wkly* 139:407-415 (2009).
75. Idorn LW, Datta P, Heydenreich J, Philipsen PA, Wulf HC: Black light visualized solar lentigines on the shoulders and upper back are associated with objectively measured UVR exposure and cutaneous malignant melanoma. *Photochem Photobiol Sci* (2014).
76. Ingvar A, Smedby KE, Lindelof B, Fernberg P, Bellocco R, Tufveson G, Hoglund P, Adami J: Immunosuppressive treatment after solid organ transplantation and risk of post-transplant cutaneous squamous cell carcinoma. *Nephrol Dial Transplant* 25:2764-2771 (2010).
77. Jambusaria-Pahlajani A, Ortman S, Schmults CD, Liang C: Sequential Curettage, 5-Fluorouracil, and Photodynamic Therapy for Field Cancerization of the Scalp and Face in Solid Organ Transplant Recipients. *Dermatol Surg* 42 Suppl 1:S66-S72 (2016).
78. Jensen AO, Svaerke C, Farkas D, Pedersen L, Kragballe K, Sorensen HT: Skin cancer risk among solid organ recipients: a nationwide cohort study in Denmark. *Acta Derm Venereol* 90:474-479 (2010).
79. Juzenas P, Iani V, Bagdonas S, Rotomskis R, Moan J: Fluorescence spectroscopy of normal mouse skin exposed to 5-aminolaevulinic acid and red light. *J Photochem Photobiol B* 61:78-86 (2001).

80. Juzeniene A, Juzenas P, Iani V, Moan J: Topical application of 5-aminolevulinic acid and its methylester, hexylester and octylester derivatives: considerations for dosimetry in mouse skin model. *Photochem Photobiol* 76:329-334 (2002).
81. Juzeniene A, Juzenas P, Ma LW, Iani V, Moan J: Topical application of 5-aminolaevulinic acid, methyl 5-aminolaevulinate and hexyl 5-aminolaevulinate on normal human skin. *Br J Dermatol* 155:791-799 (2006).
82. Karia PS, Han J, Schmulls CD: Cutaneous squamous cell carcinoma: estimated incidence of disease, nodal metastasis, and deaths from disease in the United States, 2012. *J Am Acad Dermatol* 68:957-966 (2013).
83. Karran P: Thiopurines, DNA damage, DNA repair and therapy-related cancer. *Br Med Bull* 79-80:153-170 (2006).
84. Kasiske BL, Zeier MG, Chapman JR, Craig JC, Ekberg H, Garvey CA, Green MD, Jha V, Josephson MA, Kiberd BA, Kreis HA, McDonald RA, Newmann JM, Obrador GT, Vincenti FG, Cheung M, Earley A, Raman G, Abariga S, Wagner M, Balk EM: KDIGO clinical practice guideline for the care of kidney transplant recipients: a summary. *Kidney Int* 77:299-311 (2010).
85. Kaufmann R, Spelman L, Weightman W, Reifenberger J, Szeimies RM, Verhaeghe E, Kerrouche N, Sorba V, Villemagne H, Rhodes LE: Multicentre intraindividual randomized trial of topical methyl aminolaevulinate-photodynamic therapy vs. cryotherapy for multiple actinic keratoses on the extremities. *Br J Dermatol* 158:994-999 (2008).
86. Kennedy JC, Pottier RH: Endogenous protoporphyrin IX, a clinically useful photosensitizer for photodynamic therapy. *J Photochem Photobiol B* 14:275-292 (1992).
87. Kennedy JC, Pottier RH, Pross DC: Photodynamic therapy with endogenous protoporphyrin IX: basic principles and present clinical experience. *J Photochem Photobiol B* 6:143-148 (1990).
88. Kim TY: Immunosuppression by factors released from UV-irradiated epidermal cells: selective effects on the generation of contact and delayed hypersensitivity after exposure to UVA or UVB radiation. (1990).
89. Ko DY: Fractional erbium: YAG laser-assisted photodynamic therapy for facial actinic keratoses: a randomized, comparative, prospective study. (2014).
90. Ko DY, Kim KH, Song KH: A randomised trial comparing methyl aminolaevulinate photodynamic therapy with and without Er:YAG ablative fractional laser treatment in Asian patients with lower extremity Bowen's disease: results from a 12-month follow-up. *Br J Dermatol* (2013).

91. Kollias N, Gillies R, Cohen-Goihman C, Phillips SB, Muccini JA, Stiller MJ, Drake LA: Fluorescence photography in the evaluation of hyperpigmentation in photodamaged skin. *J Am Acad Dermatol* 36:226-230 (1997).
92. Kollias N, Gillies R, Moran M, Kochevar IE, Anderson RR: Endogenous skin fluorescence includes bands that may serve as quantitative markers of aging and photoaging. *J Invest Dermatol* 111:776-780 (1998).
93. Korbek M: PDT and Inflammation, Hamblin MR, Mróz P (eds): *Advances in Photodynamic therapy basic, translational, and clinical* 1 ed., pp 255-266 (Artech House, 2008).
94. Krieg RC, Messmann H, Rauch J, Seeger S, Knuechel R: Metabolic characterization of tumor cell-specific protoporphyrin IX accumulation after exposure to 5-aminolevulinic acid in human colonic cells. *Photochem Photobiol* 76:518-525 (2002).
95. Kripke ML: Antigenicity of murine skin tumors induced by ultraviolet light. *J Natl Cancer Inst* 53:1333-1336 (1974).
96. Kripke ML: Skin cancer, photoimmunology, and urocanic acid. *Photodermatol* 1:161-163 (1984).
97. Krisl JC, Doan VP: *Chemotherapy and Transplantation: The Role of Immunosuppression in Malignancy and a Review of Antineoplastic Agents in Solid Organ Transplant Recipients*. *Am J Transplant* 17:1974-1991 (2017).
98. Krynitz B, Edgren G, Lindelof B, Baecklund E, Brattstrom C, Wilczek H, Smedby KE: Risk of skin cancer and other malignancies in kidney, liver, heart and lung transplant recipients 1970 to 2008--a Swedish population-based study. *Int J Cancer* 132:1429-1438 (2013).
99. Krynitz B, Rozell BL, Lyth J, Smedby KE, Lindelof B: Cutaneous malignant melanoma in the Swedish organ transplantation cohort: A study of clinicopathological characteristics and mortality. *J Am Acad Dermatol* 73:106-113 (2015).
100. Lai C, August S, Albibas A, Behar R, Cho SY, Polak ME, Theaker J, MacLeod AS, French RR, Glennie MJ, Al-Shamkhani A, Healy E: OX40+ Regulatory T Cells in Cutaneous Squamous Cell Carcinoma Suppress Effector T-Cell Responses and Associate with Metastatic Potential. *Clin Cancer Res* 22:4236-4248 (2016).
101. Lai C, August S, Behar R, Polak M, Ardern-Jones M, Theaker J, Al-Shamkhani A, Healy E: Characteristics of immunosuppressive regulatory T cells in cutaneous squamous cell carcinomas and role in metastasis. *Lancet* 385 Suppl 1:S59 (2015).
102. Lanz J: *Aggressive Squamous Cell Carcinoma in Organ Transplant Recipients*. (2018).

103. Larsen HK, Thomsen LT, Haedersdal M, Dehlendorff C, Schwartz SS, Kjaer SK: Risk of genital warts in renal transplant recipients-A registry-based, prospective cohort study. *Am J Transplant* 19:156-165 (2019).
104. Lerche CM, Heerfordt IM, Heydenreich J, Wulf HC: Alternatives to Outdoor Daylight Illumination for Photodynamic Therapy--Use of Greenhouses and Artificial Light Sources. *Int J Mol Sci* 17:309 (2016).
105. Lerche CM, Philipsen PA, Wulf HC: UVR: sun, lamps, pigmentation and vitamin D. *Photochem Photobiol Sci* 16:291-301 (2017).
106. Lindelof B, Dal H, Wolk K, Malmberg N: Cutaneous squamous cell carcinoma in organ transplant recipients: a study of the Swedish cohort with regard to tumor site. *Arch Dermatol* 141:447-451 (2005).
107. Lindelof B, Jarnvik J, Ternesten-Bratel A, Granath F, Hedblad MA: Mortality and clinicopathological features of cutaneous squamous cell carcinoma in organ transplant recipients: a study of the Swedish cohort. *Acta Derm Venereol* 86:219-222 (2006).
108. Lippert J, Smucler R, Vlk M: Fractional carbon dioxide laser improves nodular basal cell carcinoma treatment with photodynamic therapy with methyl 5-aminolevulinate. *Dermatol Surg* 39:1202-1208 (2013).
109. Liu Y, Viau G, Bissonnette R: Multiple large-surface photodynamic therapy sessions with topical or systemic aminolevulinic acid and blue light in UV-exposed hairless mice. *J Cutan Med Surg* 8:131-139 (2004).
110. Lock-Andersen J, Knudstorp ND, Wulf HC: Facultative skin pigmentation in caucasians: an objective biological indicator of lifetime exposure to ultraviolet radiation? *Br J Dermatol* 138:826-832 (1998).
111. Lumbang W, Stasko T: Management of skin cancer after organ transplantation. *G Ital Dermatol Venereol* 146:341-352 (2011).
112. Madeleine MM, Patel NS, Plasmeijer EI, Engels EA, Bouwes Bavinck JN, Toland AE, Green AC: Epidemiology of keratinocyte carcinomas after organ transplantation. *Br J Dermatol* (2017).
113. Manstein D, Herron GS, Sink RK, Tanner H, Anderson RR: Fractional photothermolysis: a new concept for cutaneous remodeling using microscopic patterns of thermal injury. *Lasers Surg Med* 34:426-438 (2004).
114. Ming M, Zhao B, Qiang L, He YY: Effect of immunosuppressants tacrolimus and mycophenolate mofetil on the keratinocyte UVB response. *Photochem Photobiol* 91:242-247 (2015).

115. Moan J, Juzeniene A: The Role of Oxygen in Photodynamic Therapy, Hamblin MR, Mroz P (eds): *Advances in Photodynamic Therapy. Basic, Translational, and Clinical* 1 ed., pp 135-149 (Artech House, Boston 2008).
116. Monnier VM, Vishwanath V, Frank KE, Elmets CA, Dauchot P, Kohn RR: Relation between complications of type I diabetes mellitus and collagen-linked fluorescence. *N Engl J Med* 314:403-408 (1986).
117. Morton C, Szeimies RM, Sidoroff A, Wennberg AM, Basset-Seguin N, Calzavara-Pinton P, Gilaberte Y, Hofbauer G, Hunger R, Karrer S, Lehmann P, Piaserico S, Ulrich C, Braathen L: European Dermatology Forum Guidelines on topical photodynamic therapy. *Eur J Dermatol* 25:296-311 (2015).
118. Morton CA, Szeimies RM, Sidoroff A, Braathen LR: European guidelines for topical photodynamic therapy part 1: treatment delivery and current indications - actinic keratoses, Bowen's disease, basal cell carcinoma. *J Eur Acad Dermatol Venereol* (2012a).
119. Morton CA, Szeimies RM, Sidoroff A, Braathen LR: European guidelines for topical photodynamic therapy part 2: emerging indications - field cancerization, photorejuvenation and inflammatory/infective dermatoses. *J Eur Acad Dermatol Venereol* (2012b).
120. Morton CA, Whitehurst C, Moore JV, MacKie RM: Comparison of red and green light in the treatment of Bowen's disease by photodynamic therapy. *Br J Dermatol* 143:767-772 (2000).
121. Mostafid H, Bunce C: Improved detection and reduced early recurrence of non-muscle-invasive bladder cancer using hexaminolaevulinate fluorescence cystoscopy: results of a multicentre prospective randomized study (PC B305). *BJU Int* 104:889-890 (2009).
122. Mroz P, Szokalska A, Wu MX, Hamblin MR: Photodynamic therapy of tumors can lead to development of systemic antigen-specific immune response. *PLoS One* 5:e15194 (2010).
123. Muhlstadt M: Ingenol Mebutate vs. Daylight Photodynamic Therapy in a Kidney Transplant Recipient. *Dermatology* 232 Suppl 1:20-23 (2016).
124. Na R, Stender IM, Henriksen M, Wulf HC: Autofluorescence of human skin is age-related after correction for skin pigmentation and redness. *J Invest Dermatol* 116:536-540 (2001a).
125. Na R, Stender IM, Ma L, Wulf HC: Autofluorescence spectrum of skin: component bands and body site variations. *Skin Res Technol* 6:112-117 (2000).
126. Na R, Stender IM, Wulf HC: Can autofluorescence demarcate basal cell carcinoma from normal skin? A comparison with protoporphyrin IX fluorescence. *Acta Derm Venereol* 81:246-249 (2001b).

127. Neittaanmaki-Perttu N, Gronroos M, Karppinen TT, Tani TT, Snellman E: Hexyl-5-aminolaevulinate 0.2% vs. methyl-5-aminolaevulinate 16% daylight photodynamic therapy for treatment of actinic keratoses: results of a randomized double-blinded pilot trial. *Br J Dermatol* 174:427-429 (2016).
128. Neittaanmaki-Perttu N, Karppinen TT, Tani T, Snellman E, Gronroos M: Long-term Outcome of Low-concentration Hexyl-5-aminolaevulinate Daylight Photodynamic Therapy for Treatment of Actinic Keratoses. *Acta Derm Venereol* 97:120-121 (2017).
129. Nishigori C: Current concept of photocarcinogenesis. *Photochem Photobiol Sci* 14:1713-1721 (2015).
130. Nissen CV, Wiegell SR, Philipsen PA, Wulf HC: Short-term chemical pretreatment cannot replace curettage in photodynamic therapy. *Photodermatol Photoimmunol Photomed* 32:146-152 (2016).
131. O’Gorman SM, Clowry J, Manley M, McCavana J, Gray L, Kavanagh A, Lally A, Collins P: Artificial White Light vs Daylight Photodynamic Therapy for Actinic Keratoses: A Randomized Clinical Trial. *JAMA Dermatol* 152:638-644 (2016).
132. Olsen EA, Abernethy ML, Kulp-Shorten C, Callen JP, Glazer SD, Huntley A, McCray M, Monroe AB, Tschen E, Wolf JE, Jr.: A double-blind, vehicle-controlled study evaluating masoprocol cream in the treatment of actinic keratoses on the head and neck. *J Am Acad Dermatol* 24:738-743 (1991).
133. Omeland SH, Nielsen PS, Gjerdrum LM, Gniadecki R: Immunosuppressive Environment in Basal Cell Carcinoma: The Role of Regulatory T Cells. *Acta Derm Venereol* 96:917-921 (2016).
134. Peng Q, Moan J, Warloe T, Iani V, Steen HB, Bjorseth A, Nesland JM: Build-up of esterified aminolevulinic-acid-derivative-induced porphyrin fluorescence in normal mouse skin. *J Photochem Photobiol B* 34:95-96 (1996).
135. Perrett CM, McGregor JM, Warwick J, Karran P, Leigh IM, Proby CM, Harwood CA: Treatment of post-transplant premalignant skin disease: a randomized inpatient comparative study of 5-fluorouracil cream and topical photodynamic therapy. *Br J Dermatol* 156:320-328 (2007).
136. Perrett CM, Walker SL, O’Donovan P, Warwick J, Harwood CA, Karran P, McGregor JM: Azathioprine treatment photosensitizes human skin to ultraviolet A radiation. *Br J Dermatol* 159:198-204 (2008).
137. Piaserico S, Belloni FA, Rigotti P, Rossi B, Baldan N, Alaibac M, Marchini F: Topical photodynamic therapy of actinic keratosis in renal transplant recipients. *Transplant Proc* 39:1847-1850 (2007a).

138. Piaserico S, Belloni FA, Rigotti P, Rossi B, Baldan N, Alaibac M, Marchini F: Topical photodynamic therapy of actinic keratosis in renal transplant recipients. *Transplant Proc* 39:1847-1850 (2007b).
139. Piaserico S, Sandini E, Peserico A, Alaibac M: Cutaneous viral infections in organ transplant patients. *G Ital Dermatol Venereol* 149:409-415 (2014).
140. Pottier RH, Chow YF, LaPlante JP, Truscott TG, Kennedy JC, Beiner LA: Non-invasive technique for obtaining fluorescence excitation and emission spectra in vivo. *Photochem Photobiol* 44:679-687 (1986).
141. Proby CM, Wisgerhof HC, Casabonne D, Green AC, Harwood CA, Bouwes Bavinck JN: The epidemiology of transplant-associated keratinocyte cancers in different geographical regions. *Cancer Treat Res* 146:75-95 (2009).
142. Quint KD, Genders RE, de Koning MN, Borgogna C, Gariglio M, Bouwes Bavinck JN, Doorbar J, Feltkamp MC: Human Beta-papillomavirus infection and keratinocyte carcinomas. *J Pathol* 235:342-354 (2015).
143. Ramsay HM, Fryer AA, Hawley CM, Smith AG, Harden PN: Non-melanoma skin cancer risk in the Queensland renal transplant population. *Br J Dermatol* 147:950-956 (2002).
144. Ramsay HM, Reece SM, Fryer AA, Smith AG, Harden PN: Seven-year prospective study of nonmelanoma skin cancer incidence in U.K. renal transplant recipients. *Transplantation* 84:437-439 (2007).
145. Redmond RM: Photophysics and photochemistry in Photodynamic Therapy, Hamblin MR, Mroz P (eds): *Advances in Photodynamic therapy. Basic, Translational, and Clinical* 1 ed., pp 41-58 (Artech House, Boston 2008).
146. Sandby-Moller J, Thieden E, Philipsen PA, Heydenreich J, Wulf HC: Skin autofluorescence as a biological UVR dosimeter. *Photodermatol Photoimmunol Photomed* 20:33-40 (2004).
147. Santos-Juanes J, Esteve A, Mas-Vidal A, Coto-Segura P, Salgueiro E, Gomez E, Galache OC: Acute renal failure caused by imiquimod 5% cream in a renal transplant patient: review of the literature on side effects of imiquimod. *Dermatology* 222:109-112 (2011).
148. Schwarz A, Noordegraaf M, Maeda A, Torii K, Clausen BE, Schwarz T: Langerhans cells are required for UVR-induced immunosuppression. *J Invest Dermatol* 130:1419-1427 (2010).
149. Schwarz A, Schwarz T: UVR-induced regulatory T cells switch antigen-presenting cells from a stimulatory to a regulatory phenotype. *J Invest Dermatol* 130:1914-1921 (2010).

150. Schwarz T: Mechanisms of UV-induced immunosuppression. *Keio J Med* 54:165-171 (2005a).
151. Schwarz T: Regulatory T cells induced by ultraviolet radiation. *Int Arch Allergy Immunol* 137:187-193 (2005b).
152. Sharfaei S, Juzenas P, Moan J, Bissonnette R: Weekly topical application of methyl aminolevulinate followed by light exposure delays the appearance of UV-induced skin tumours in mice. *Arch Dermatol Res* 294:237-242 (2002).
153. Shin MK, Choi JH, Ahn SB, Lee MH: Histologic comparison of microscopic treatment zones induced by fractional lasers and radiofrequency. *J Cosmet Laser Ther* 16:317-323 (2014).
154. Shreedhar V, Giese T, Sung VW, Ullrich SE: A cytokine cascade including prostaglandin E2, IL-4, and IL-10 is responsible for UV-induced systemic immune suppression. *J Immunol* 160:3783-3789 (1998).
155. Sitek JC, Tangeraas T, Bjerre A, Helsing P: The prevalence of skin disorders in Norwegian paediatric renal transplant recipients. *Acta Derm Venereol* 94:421-424 (2014).
156. SLAUGHTER DP, SOUTHWICK HW, SMEJKAL W: Field cancerization in oral stratified squamous epithelium; clinical implications of multicentric origin. *Cancer* 6:963-968 (1953).
157. Stender IM, Bech-Thomsen N, Poulsen T, Wulf HC: Photodynamic therapy with topical delta-aminolevulinic acid delays UV photocarcinogenesis in hairless mice. *Photochem Photobiol* 66:493-496 (1997).
158. Surber C, Pittelkow M, Lautenschlager S: Photoprotection in transplant recipients. *Curr Probl Dermatol* 43:171-196 (2012).
159. Szeimies RM, Radny P, Sebastian M, Borrosch F, Dirschka T, Krahn-Senftleben G, Reich K, Pabst G, Voss D, Foguet M, Gahlmann R, Lubbert H, Reinhold U: Photodynamic therapy with BF-200 ALA for the treatment of actinic keratosis: results of a prospective, randomized, double-blind, placebo-controlled phase III study. *Br J Dermatol* 163:386-394 (2010a).
160. Szeimies RM, Stockfleth E, Popp G, Borrosch F, Bruning H, Dominicus R, Mensing H, Reinhold U, Reich K, Moor AC, Stocker M, Ortland C, Brunnert M, Hauschild A: Long-term follow-up of photodynamic therapy with a self-adhesive 5-aminolaevulinic acid patch: 12 months data. *Br J Dermatol* 162:410-414 (2010b).
161. Szeimies RM, Torezan L, Niwa A, Valente N, Unger P, Kohl E, Schreml S, Babilas P, Karrer S, Festa-Neto C: Clinical, histopathological and immunohistochemical assessment of human skin field cancerization before and after photodynamic therapy. *Br J Dermatol* 167:150-159 (2012).

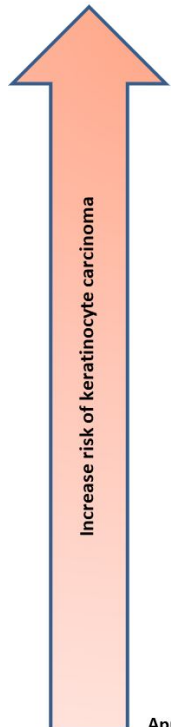
162. Takema Y, Yorimoto Y, Ohsu H, Osanai O, Kawai M: Age-related discontinuous changes in the in vivo fluorescence of human facial skin. *J Dermatol Sci* 15:55-58 (1997).
163. Taudorf EH, Haak CS, Erlendsson AM, Philipsen PA, Anderson RR, Paasch U, Haedersdal M: Fractional ablative erbium YAG laser: histological characterization of relationships between laser settings and micropore dimensions. *Lasers Surg Med* 46:281-289 (2014a).
164. Taudorf EH, Haak CS, Erlendsson AM, Philipsen PA, Anderson RR, Paasch U, Haedersdal M: Fractional ablative erbium YAG laser: histological characterization of relationships between laser settings and micropore dimensions. *Lasers Surg Med* 46:281-289 (2014b).
165. Terhorst D, Drecoll U, Stockfleth E, Ulrich C: Organ transplant recipients and skin cancer: assessment of risk factors with focus on sun exposure. *Br J Dermatol* 161 Suppl 3:85-89 (2009).
166. Tewari A, Gryns K, Kollet J, Sarkany R, Young AR: Upregulation of MMP12 and its activity by UVA1 in human skin: potential implications for photoaging. *J Invest Dermatol* 134:2598-2609 (2014).
167. Thieden E, Collins SM, Philipsen PA, Murphy GM, Wulf HC: Ultraviolet exposure patterns of Irish and Danish gardeners during work and leisure. *Br J Dermatol* 153:795-801 (2005a).
168. Thieden E, Philipsen PA, Sandby-Moller J, Wulf HC: Sunscreen use related to UV exposure, age, sex, and occupation based on personal dosimeter readings and sun-exposure behavior diaries. *Arch Dermatol* 141:967-973 (2005b).
169. Thieden E, Philipsen PA, Wulf HC: Ultraviolet radiation exposure pattern in winter compared with summer based on time-stamped personal dosimeter readings. *Br J Dermatol* 154:133-138 (2006).
170. Togsverd-Bo K, Haak CS, Thaysen-Petersen D, Wulf HC, Anderson RR, Haedersdal M: Intensified photodynamic therapy of actinic keratoses with fractional CO₂ laser: a randomized clinical trial. *Br J Dermatol* 166:1262-1269 (2012a).
171. Togsverd-Bo K, Haak CS, Thaysen-Petersen D, Wulf HC, Anderson RR, Haedersdal M: Intensified photodynamic therapy of actinic keratoses with fractional CO₂ laser: a randomized clinical trial. *Br J Dermatol* 166:1262-1269 (2012b).
172. Togsverd-Bo K, Idorn LW, Philipsen PA, Wulf HC, Haedersdal M: Protoporphyrin IX formation and photobleaching in different layers of normal human skin: methyl- and hexylaminolevulinate and different light sources. *Exp Dermatol* 21:745-750 (2012c).

173. Togsverd-Bo K, Lei U, Erlendsson AM, Taudorf EH, Philipsen PA, Wulf HC, Skov L, Haedersdal M: Combination of ablative fractional laser and daylight-mediated photodynamic therapy for actinic keratosis in organ transplant recipients - a randomized controlled trial. *Br J Dermatol* 172:467-474 (2015).
174. Togsverd-Bo K, Lerche CM, Poulsen T, Wulf HC, Haedersdal M: Photodynamic therapy with topical methyl- and hexylaminolevulinate for prophylaxis and treatment of UV-induced SCC in hairless mice. *Exp Dermatol* 19:e166-e172 (2010).
175. Tyrrell JS, Morton C, Campbell SM, Curnow A: Comparison of protoporphyrin IX accumulation and destruction during methylaminolevulinate photodynamic therapy of skin tumours located at acral and nonacral sites. *Br J Dermatol* 164:1362-1368 (2011).
176. Uehlinger P, Zellweger M, Wagnieres G, Juillerat-Jeanneret L, van den Bergh H, Lange N: 5-Aminolevulinic acid and its derivatives: physical chemical properties and protoporphyrin IX formation in cultured cells. *J Photochem Photobiol B* 54:72-80 (2000).
177. Ullrich SE: The immunologic revolution: photoimmunology. (2012).
178. Ullrich SE, Byrne SN: The immunologic revolution: photoimmunology. *J Invest Dermatol* 132:896-905 (2012).
179. Ulrich C, Bichel J, Euvrard S, Guidi B, Proby CM, van de Kerkhof PC, Amerio P, Ronnevig J, Slade HB, Stockfleth E: Topical immunomodulation under systemic immunosuppression: results of a multicentre, randomized, placebo-controlled safety and efficacy study of imiquimod 5% cream for the treatment of actinic keratoses in kidney, heart, and liver transplant patients. *Br J Dermatol* 157 Suppl 2:25-31 (2007).
180. Ulrich C, Busch JO, Meyer T, Nindl I, Schmook T, Sterry W, Stockfleth E: Successful treatment of multiple actinic keratoses in organ transplant patients with topical 5% imiquimod: a report of six cases. *Br J Dermatol* 155:451-454 (2006).
181. Ulrich C, Hackethal M, Meyer T, Geusau A, Nindl I, Ulrich M, Forschner T, Sterry W, Stockfleth E: Skin infections in organ transplant recipients. *J Dtsch Dermatol Ges* 6:98-105 (2008).
182. Ulrich C, Johannsen A, Rowert-Huber J, Ulrich M, Sterry W, Stockfleth E: Results of a randomized, placebo-controlled safety and efficacy study of topical diclofenac 3% gel in organ transplant patients with multiple actinic keratoses. *Eur J Dermatol* 20:482-488 (2010).
183. Vatve M, Ortonne JP, Birch-Machin MA, Gupta G: Management of field change in actinic keratosis. *Br J Dermatol* 157 Suppl 2:21-24 (2007).

184. Vink AA, Moodycliffe AM, Shreedhar V, Ullrich SE, Roza L, Yarosh DB, Kripke ML: The inhibition of antigen-presenting activity of dendritic cells resulting from UV irradiation of murine skin is restored by in vitro photorepair of cyclobutane pyrimidine dimers. *Proc Natl Acad Sci U S A* 94:5255-5260 (1997).
185. Wallingford SC, Russell SA, Vail A, Proby CM, Lear JT, Green AC: Actinic keratoses, actinic field change and associations with squamous cell carcinoma in renal transplant recipients in Manchester, UK. *Acta Derm Venereol* 95:830-834 (2015).
186. Wenande E: Efficacy and safety of daylight photodynamic therapy after tailored pretreatment with ablative fractional laser or microdermabrasion: a randomized, side-by-side, single-blind trial in patients with actinic keratosis and large-area field cancerization. (2019).
187. Wennberg AM, Stenquist B, Stockfleth E, Keohane S, Lear JT, Jemec G, Mork C, Christensen E, Kapp A, Solvsten H, Talme T, Berne B, Forschner T: Photodynamic therapy with methyl aminolevulinate for prevention of new skin lesions in transplant recipients: a randomized study. *Transplantation* 86:423-429 (2008).
188. Werner RN, Sammain A, Erdmann R, Hartmann V, Stockfleth E, Nast A: The natural history of actinic keratosis: a systematic review. *Br J Dermatol* 169:502-518 (2013).
189. WHO: IARC monographs on the evaluation of carcinogenic risk to humans, Solar and Ultraviolet Radiation, 55 ed, pp 1-316 1992).
190. Wiegell SR, Fabricius S, Heydenreich J, Enk CD, Rosso S, Baumler W, Baldursson BT, Wulf HC: Weather conditions and daylight-mediated photodynamic therapy: protoporphyrin IX-weighted daylight doses measured in six geographical locations. *Br J Dermatol* 168:186-191 (2013).
191. Wiegell SR, Haedersdal M, Philipsen PA, Eriksen P, Enk CD, Wulf HC: Continuous activation of PpIX by daylight is as effective as and less painful than conventional photodynamic therapy for actinic keratoses; a randomized, controlled, single-blinded study. *Br J Dermatol* 158:740-746 (2008a).
192. Wiegell SR, Heydenreich J, Fabricius S, Wulf HC: Continuous ultra-low-intensity artificial daylight is not as effective as red LED light in photodynamic therapy of multiple actinic keratoses. *Photodermatol Photoimmunol Photomed* 27:280-285 (2011).
193. Wiegell SR, Skiveren J, Philipsen PA, Wulf HC: Pain during photodynamic therapy is associated with protoporphyrin IX fluorescence and fluence rate. *Br J Dermatol* 158:727-733 (2008b).
194. Wiegell SR, Wulf HC: Photodynamic therapy of acne vulgaris using 5-aminolevulinic acid versus methyl aminolevulinate. *J Am Acad Dermatol* 54:647-651 (2006).

195. Wiegell SR, Wulf HC, Szeimies RM, Basset-Seguín N, Bissonnette R, Gerritsen MJ, Gilaberte Y, Calzavara-Pinton P, Morton CA, Sidoroff A, Braathen LR: Daylight photodynamic therapy for actinic keratosis: an international consensus: International Society for Photodynamic Therapy in Dermatology. *J Eur Acad Dermatol Venereol* 26:673-679 (2012).
196. Willey A, Mehta S, Lee PK: Reduction in the incidence of squamous cell carcinoma in solid organ transplant recipients treated with cyclic photodynamic therapy. *Dermatol Surg* 36:652-658 (2010).
197. Wisgerhof HC, Edelbroek JR, de Fijter JW, Feltkamp MC, Willemze R, Bouwes Bavinck JN: Trends of skin diseases in organ-transplant recipients transplanted between 1966 and 2006: a cohort study with follow-up between 1994 and 2006. *Br J Dermatol* 162:390-396 (2010).
198. Wulf HC, Eriksen P: [UV index and its implications]. *Ugeskr Laeger* 172:1277-1279 (2010).
199. Wulf HC, Pavel S, Stender I, Bakker-Wensveen CA: Topical photodynamic therapy for prevention of new skin lesions in renal transplant recipients. *Acta Derm Venereol* 86:25-28 (2006).
200. Wulf HC, Sandby-Møller J, Kobayasi T, Gniadecki R: Skin aging and natural photoprotection. *Micron* 35:185-191 (2004).
201. Yamauchi M, Prisanh P, Haque Z, Woodley DT: Collagen cross-linking in sun-exposed and unexposed sites of aged human skin. *J Invest Dermatol* 97:938-941 (1991).
202. Yarosh D, Dong K, Smiles K: UV-induced degradation of collagen I is mediated by soluble factors released from keratinocytes. *Photochem Photobiol* 84:67-68 (2008).
203. Young AR: Cumulative effects of ultraviolet radiation on the skin: cancer and photoaging. *Semin Dermatol* 9:25-31 (1990).
204. Young AR: Chromophores in human skin. *Phys Med Biol* 42:789-802 (1997).
205. Zwald FO, Brown M: Skin cancer in solid organ transplant recipients: advances in therapy and management: part I. Epidemiology of skin cancer in solid organ transplant recipients. *J Am Acad Dermatol* 65:253-261 (2011a).
206. Zwald FO, Brown M: Skin cancer in solid organ transplant recipients: advances in therapy and management: part II. Management of skin cancer in solid organ transplant recipients. *J Am Acad Dermatol* 65:263-279 (2011b).

11 Appendix



Drug	Type	Mechanism of Action	Carcinogenic effects
Azathioprine	Antimetabolite	Metabolizes into 6-thioguanine and is incorporated into DNA of proliferating lymphocytes resulting in: <ul style="list-style-type: none"> • apoptosis of CD4⁺ T cells • inhibit expression of inflammatory genes in activated T-cells 	<ul style="list-style-type: none"> • 6-thioguanine incorporated into keratinocyte DNA enhances UVA absorption, which generates ROS formation and increases DNA damage
Cyclosporine	Calcineurin inhibitor	Blocks antigen-stimulated transcription of pro-inflammatory cytokines (IL2, IL-4, IFN- γ) by inhibiting calcineurin signaling pathway	<ul style="list-style-type: none"> • Potentiates UVAs induction of oncogenic activation transcription factor. • Suppress p53 activity and p53 dependent senescence in keratinocytes
Mycophenolate mofetil/ Mycophenolic acid	Antimetabolite	Inhibit proliferation of lymphocytes and production of antibodies. Inhibit expression of lymphocyte adhesion molecules and lymphocyte recruitment	<ul style="list-style-type: none"> • Impairs repair of UVB-induced DNA damage in <i>in vivo</i> keratinocytes
Tacrolimus	Calcineurin inhibitor	Blocks antigen-stimulated transcription of pro-inflammatory cytokines (IL2, IL-4, IFN- γ) by inhibiting calcineurin signaling pathway	<ul style="list-style-type: none"> • Impairs repair of UVB-induced DNA damage in <i>in vivo</i> keratinocytes • Inhibits UVB-induced checkpoint signaling
Sirolimus	mTOR inhibitor	Inhibit mTOR blocking response to proinflammatory cytokines, decreasing cell proliferation and promote differentiation of naive T-cells into CD8 ⁺ memory T-cells	<ul style="list-style-type: none"> • Anti-proliferative effects by reducing angiogenesis and modulates UVR-induced inflammation
Everolimus	mTOR inhibitor	Same as for sirolimus	<ul style="list-style-type: none"> • Same as for sirolimus
Steroids	Glycocorticoid	Reduces <u>lymfocyte</u> migration to organ graft <u>Supress</u> TNF- α and IL1+2 activity Shift from Th1 to Th2 functions	<ul style="list-style-type: none"> • No or limited effect

Appendix 1. Immunosuppressant overview. 6-TG, IL: interleukin, IFN: interferon, mTOR: mammalian target of rapamycin, TNF- α : tumor necrosis factor alfa.